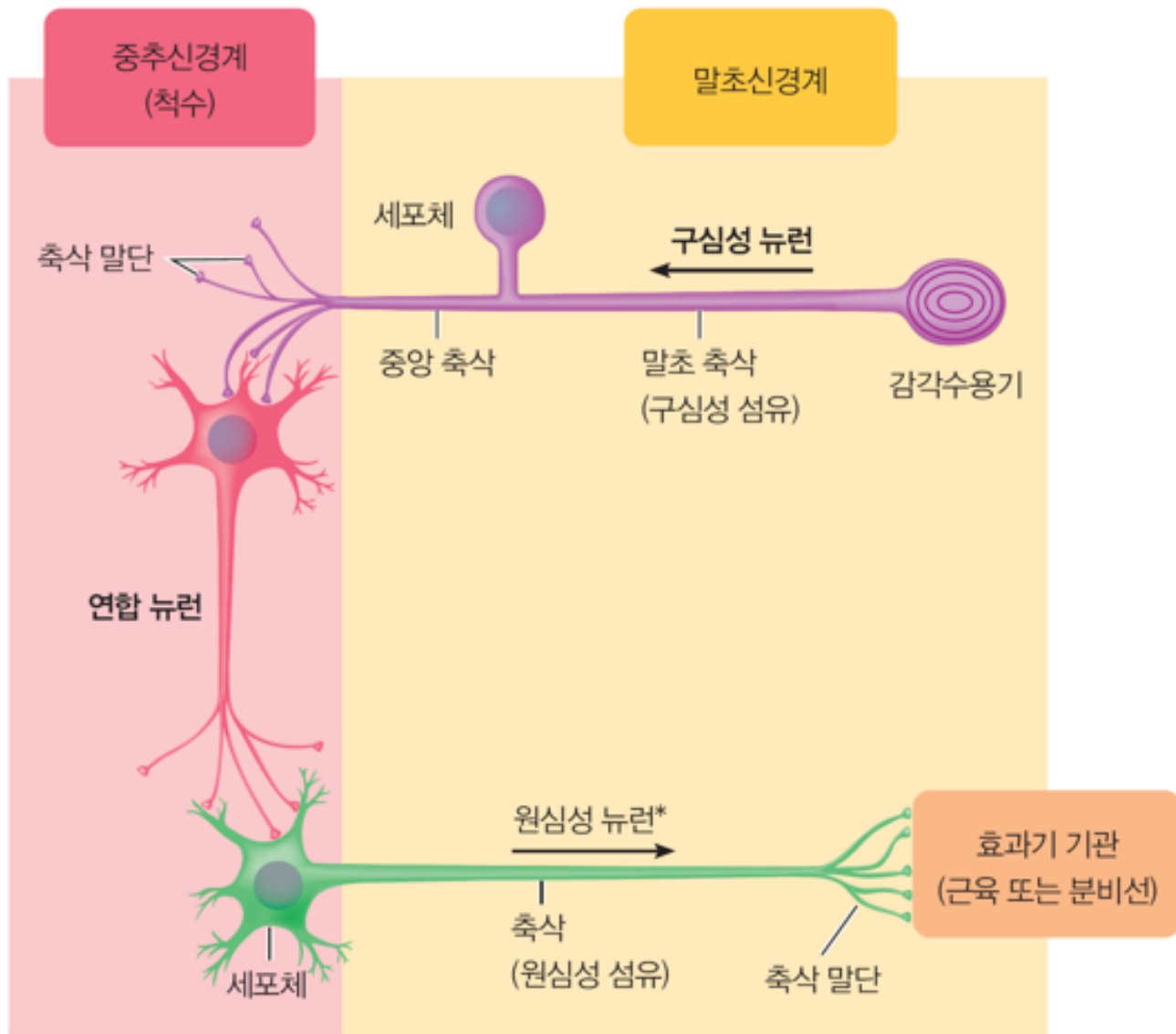


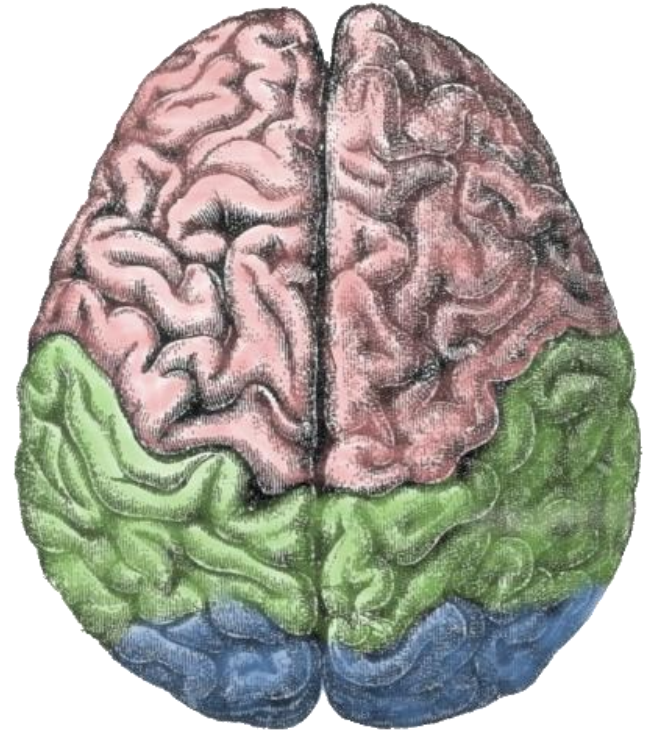
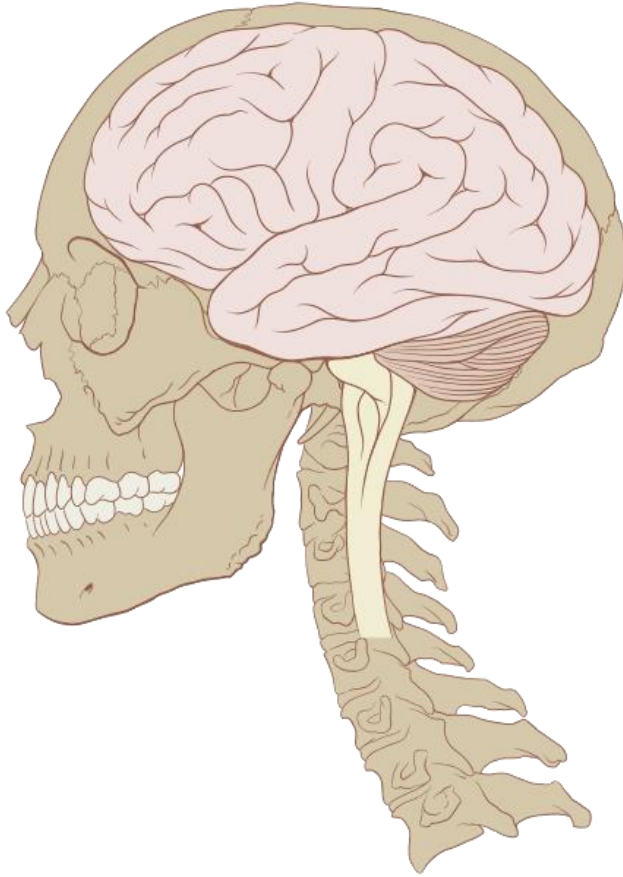# **The Nervous System II**

## **Central Nervous System (CNS)**



\*원심성 자율신경 경로는 CNS와 효과기 기관 사이에 2개 뉴런의 연결로 구성된다.

# Brain



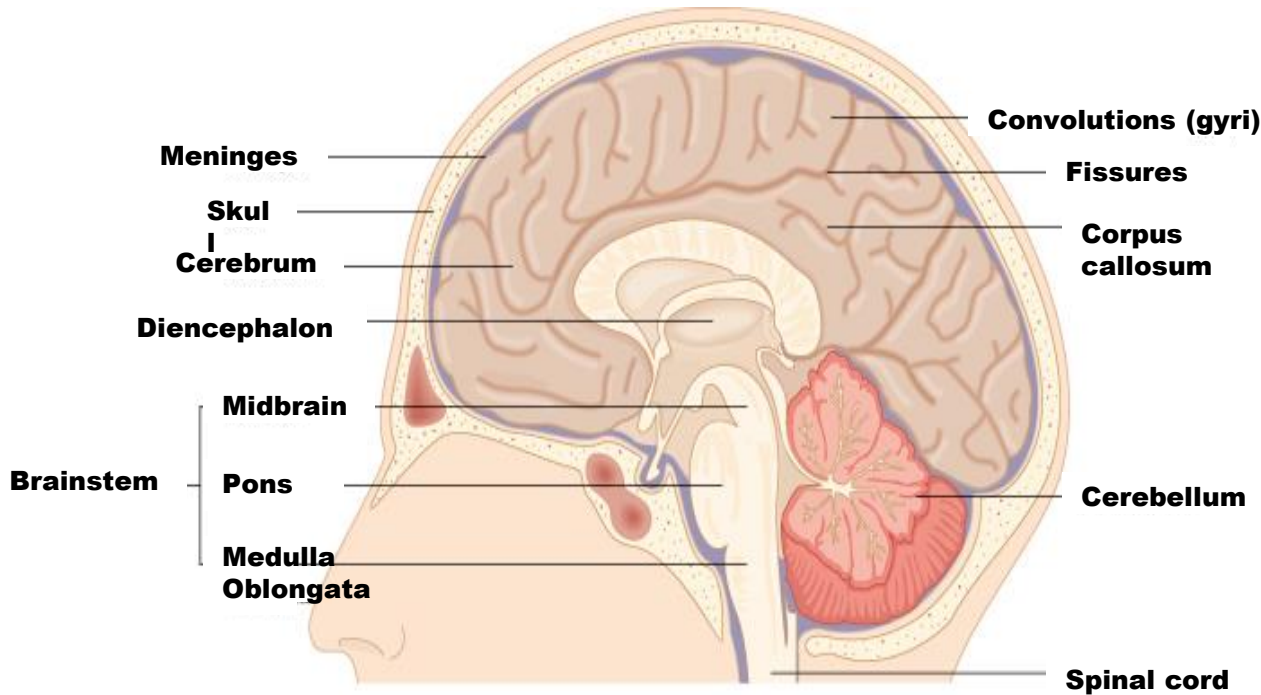
# Structure and Function

## Central Nervous System

- **Consists of the brain and spinal cord**
- **The control center of the body responsible for controlling, receiving, and interpreting all stimuli**
- **Sends nerve impulses to instruct muscles and glands to take or respond to certain actions**
- **Both voluntary and involuntary movements are controlled**

# Structure and Function

## Brain



- **Weighs about 1.2~1.6kg in adults**
- **75% water**
- **Contains over 100 billion neurons**
- **Controls bodily functions and interactions with the outside world**

## Divisions of the Brain

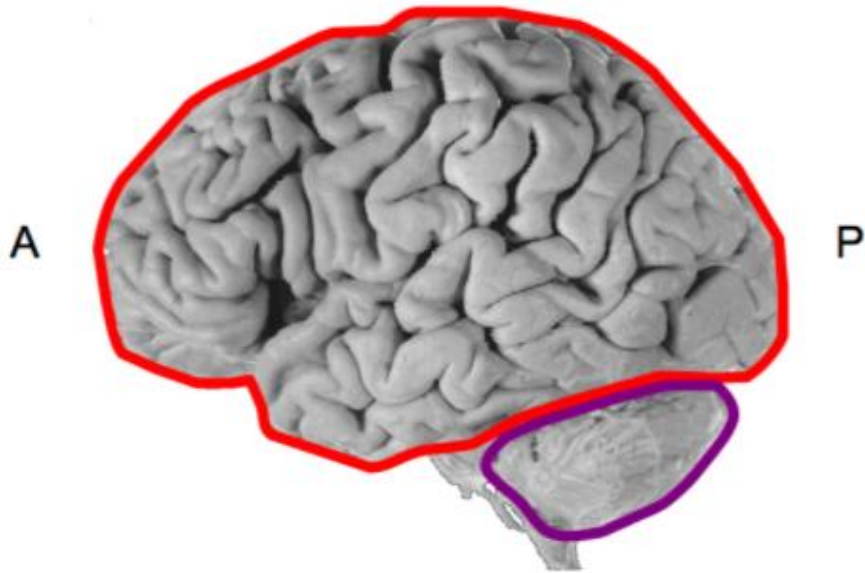
• **Brainstem**  
(뇌간)

• **Cerebellum**  
(소뇌)

• **Diencephalon**  
(간뇌; 사이뇌)

• **Cerebrum**  
(대뇌)

# Components of the Brain

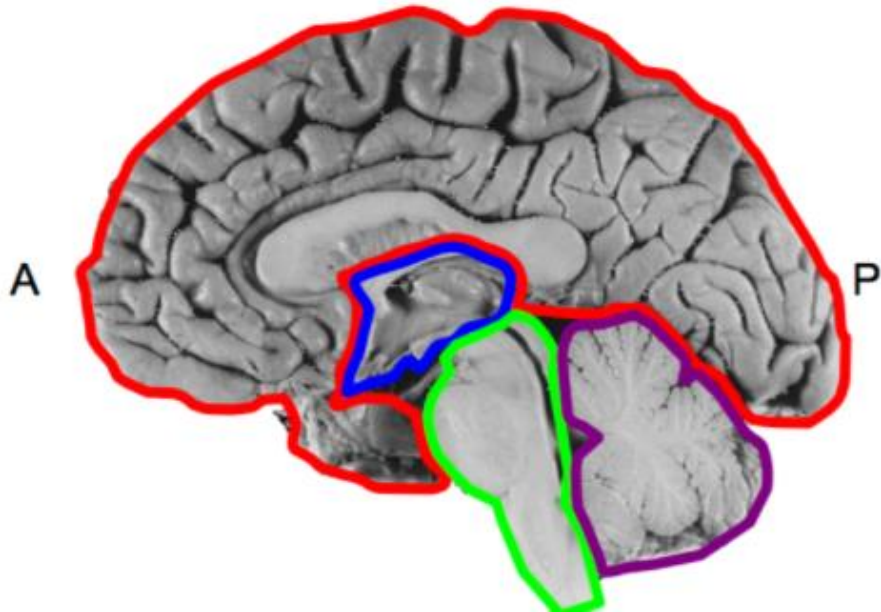


**Telencephalon (Forebrain)**

**Diencephalon ("Between Brain")**

**Brainstem**

**Cerebellum**



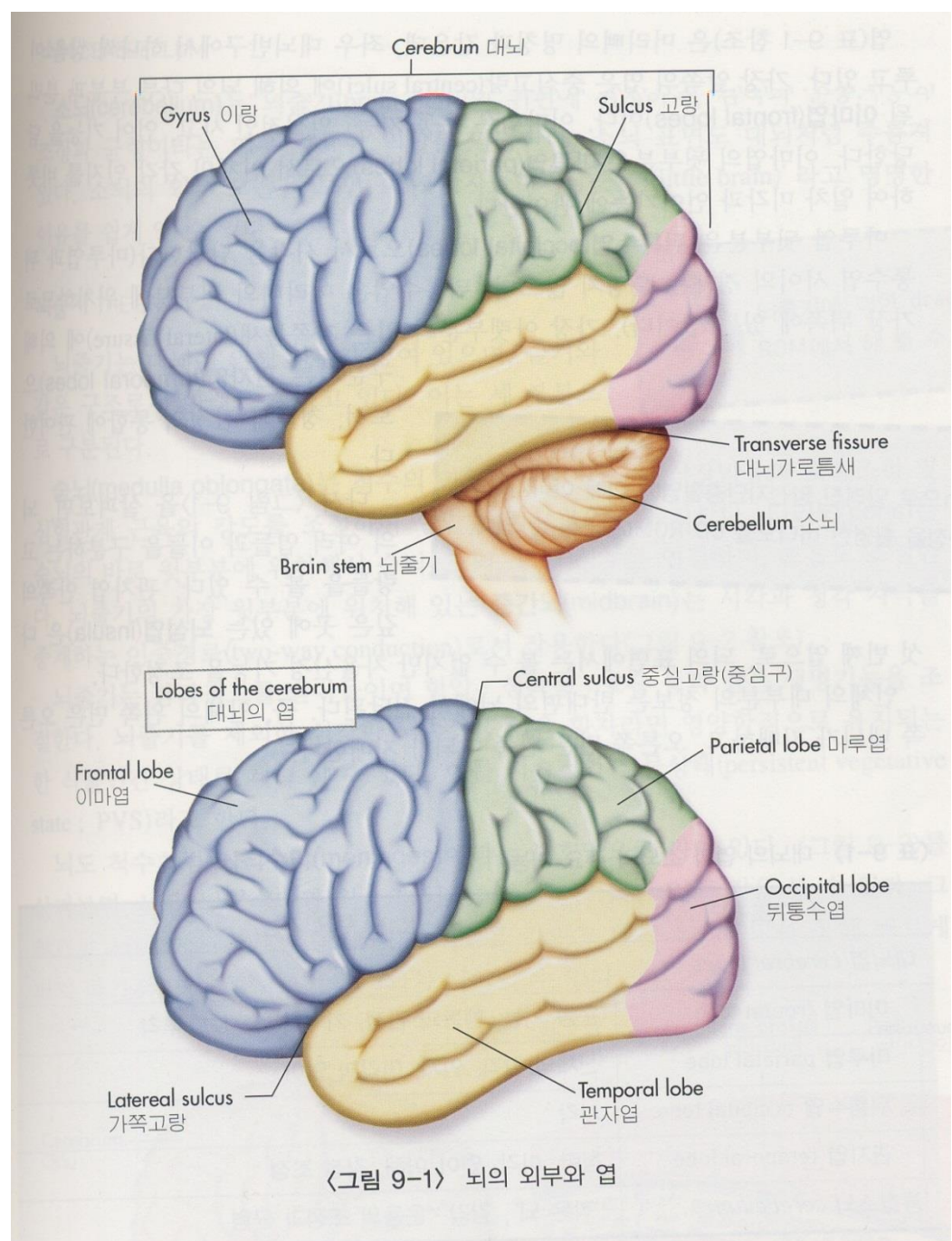
# 뇌 (Brain)

- 모든 행동 통합, 조절
- 두개골로 보호, 3겹막, 무게 (1,200~1,600 g)

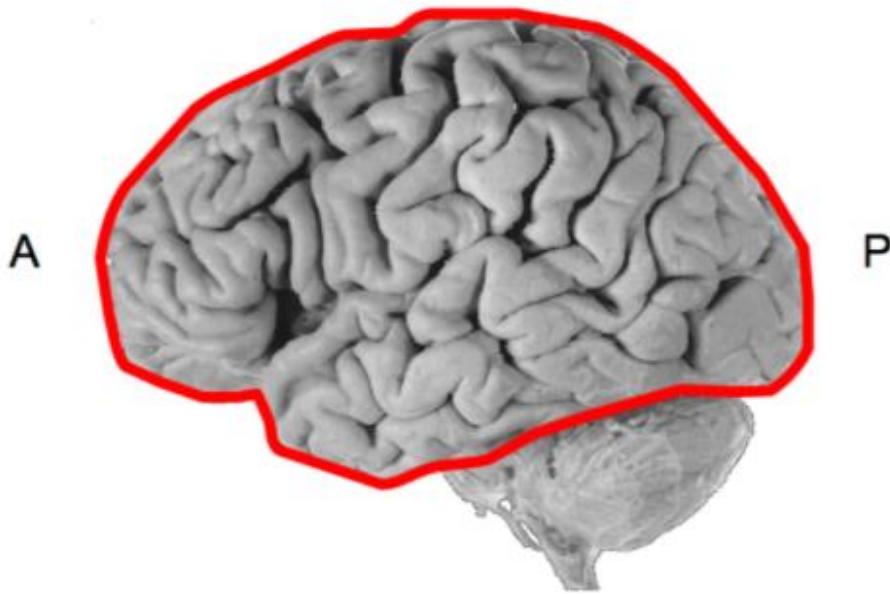
## 뇌의 외부구조

- 대뇌(cerebrum)
- 소뇌(cerebellum)
- 뇌간(brain stem)

뇌의 발생: 외배엽

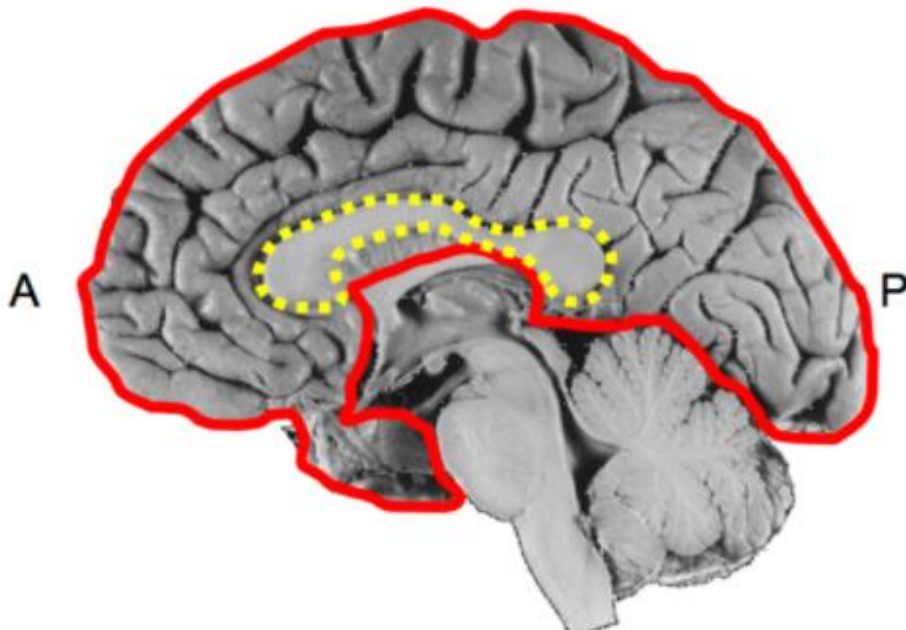


# Components of the Brain



## Telencephalon (Forebrain)

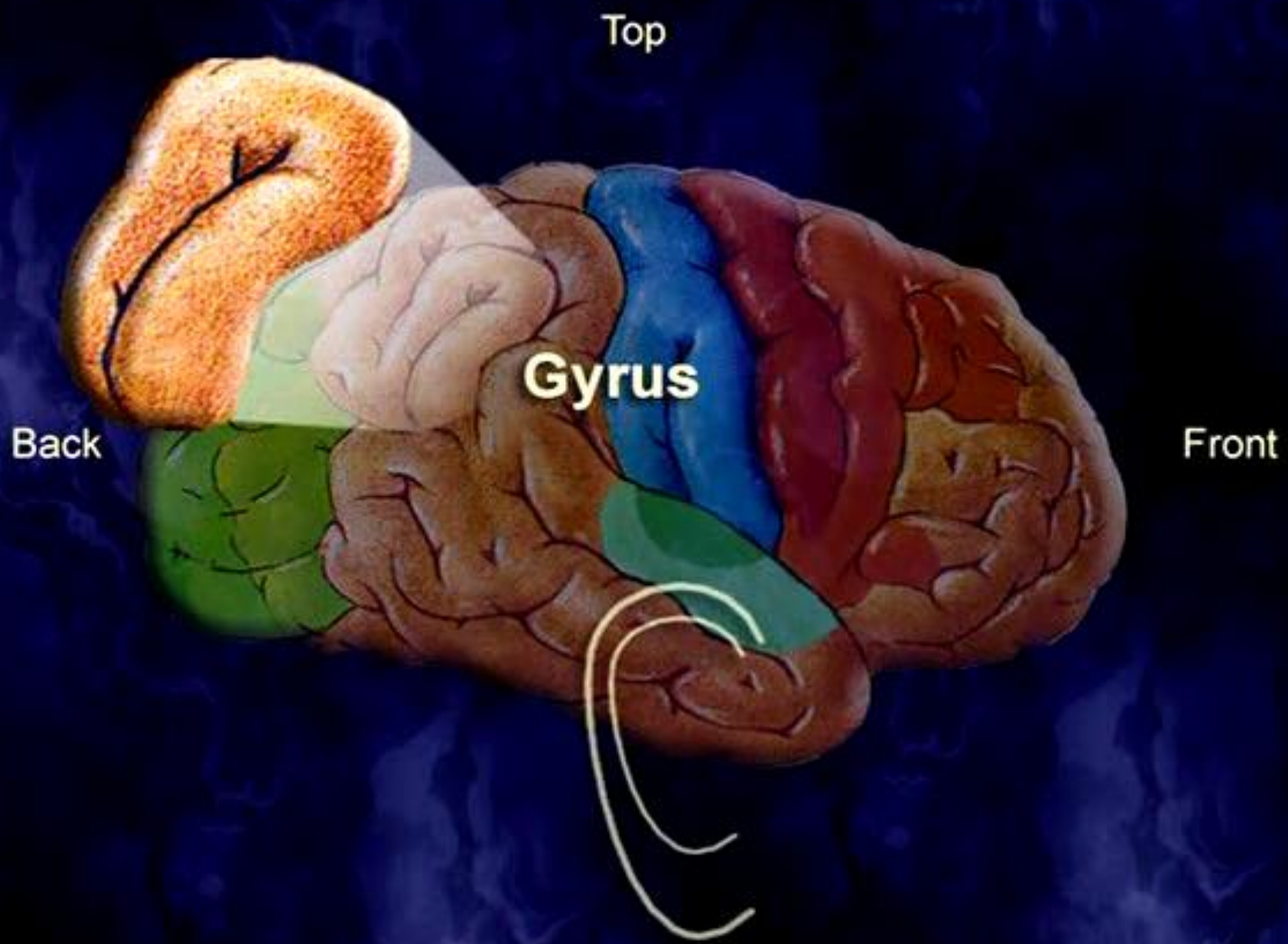
- Cerebral cortex
- Subcortical white matter
- Subcortical gray nuclei (basal nuclei)



## Corpus callosum

Major white matter tract connecting the two cerebral hemispheres



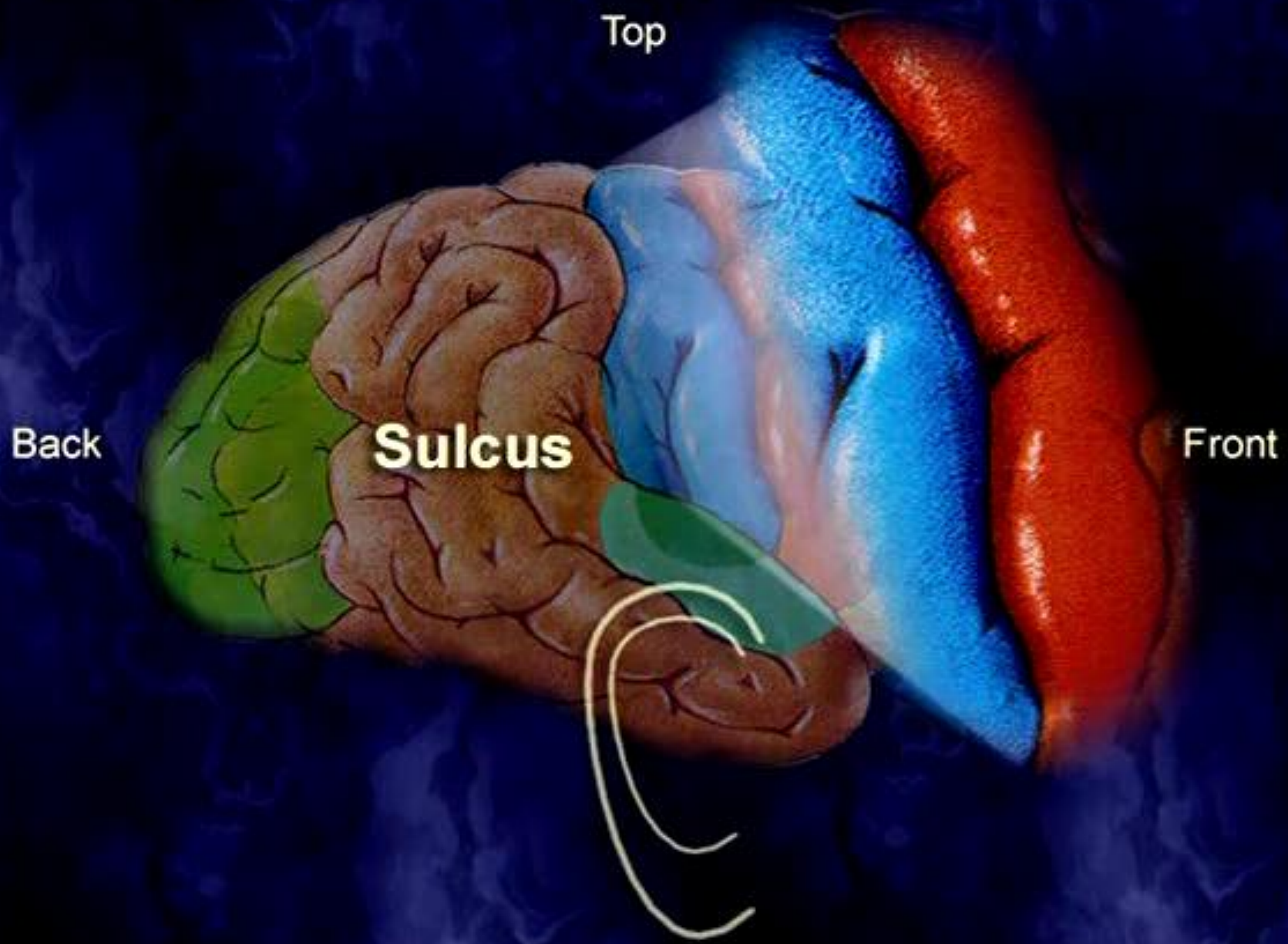


Top

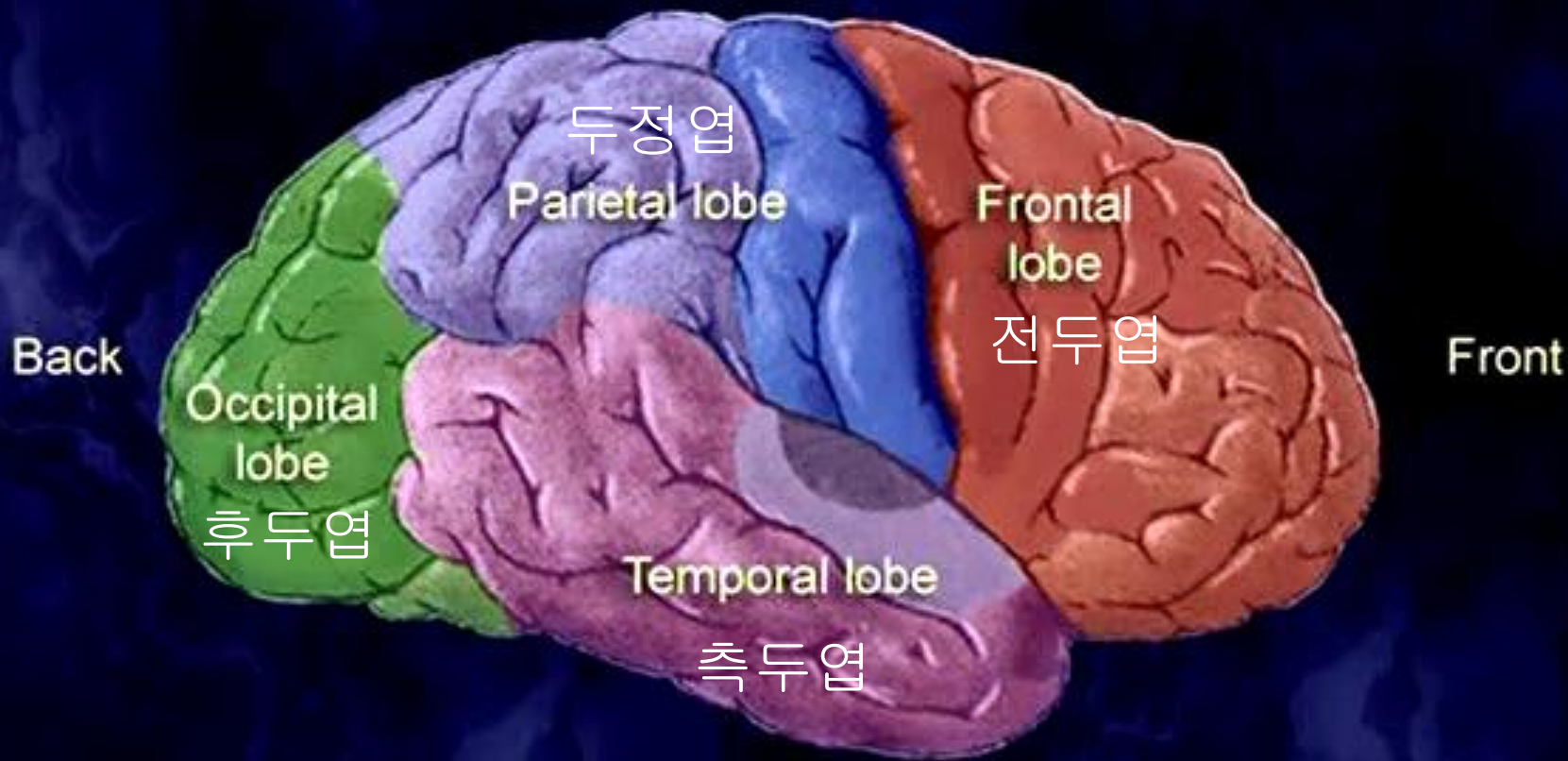
Back

Front

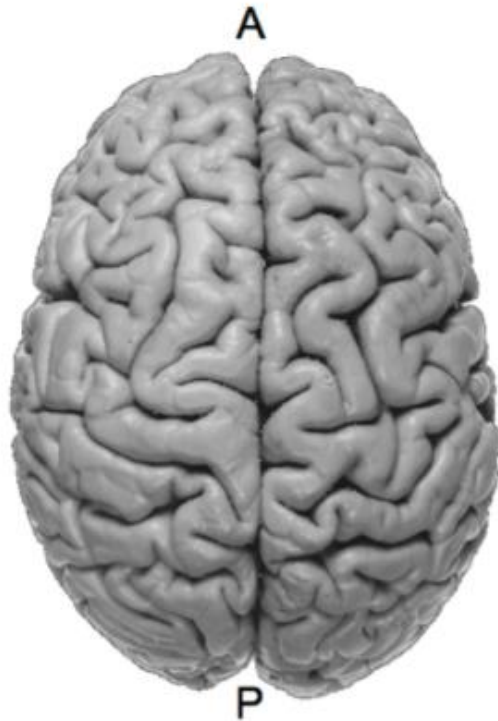Gyrus



Top

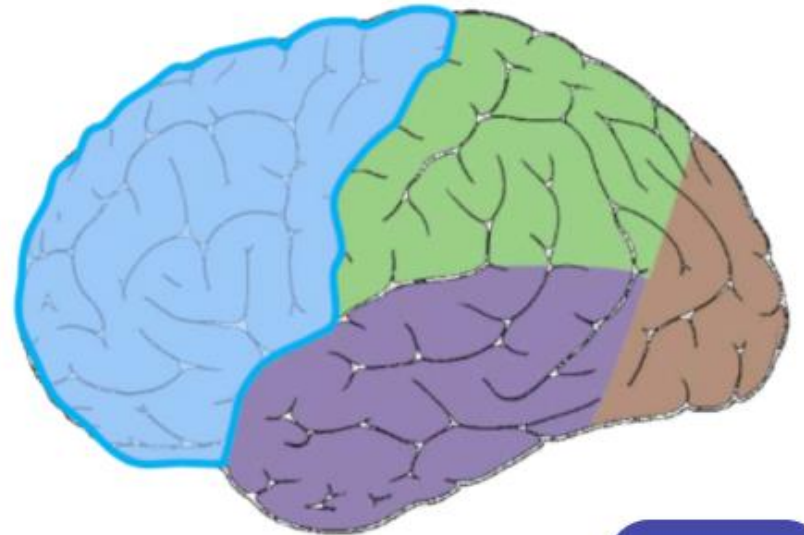
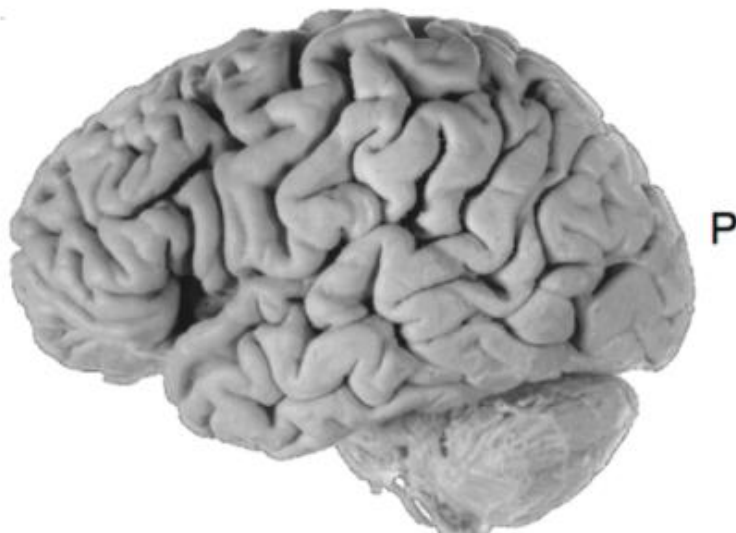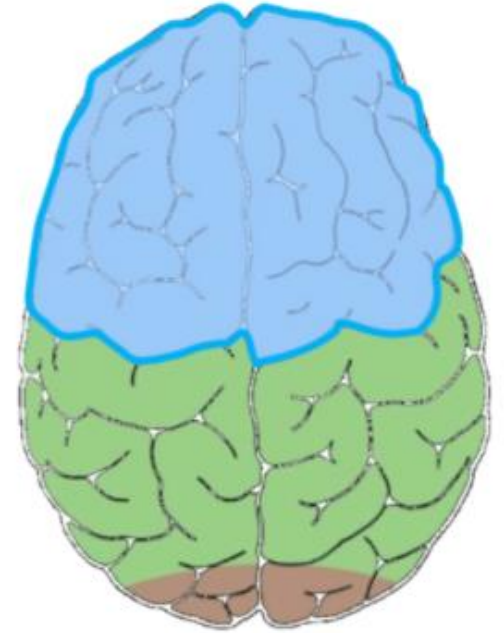


# Cortical Lobes



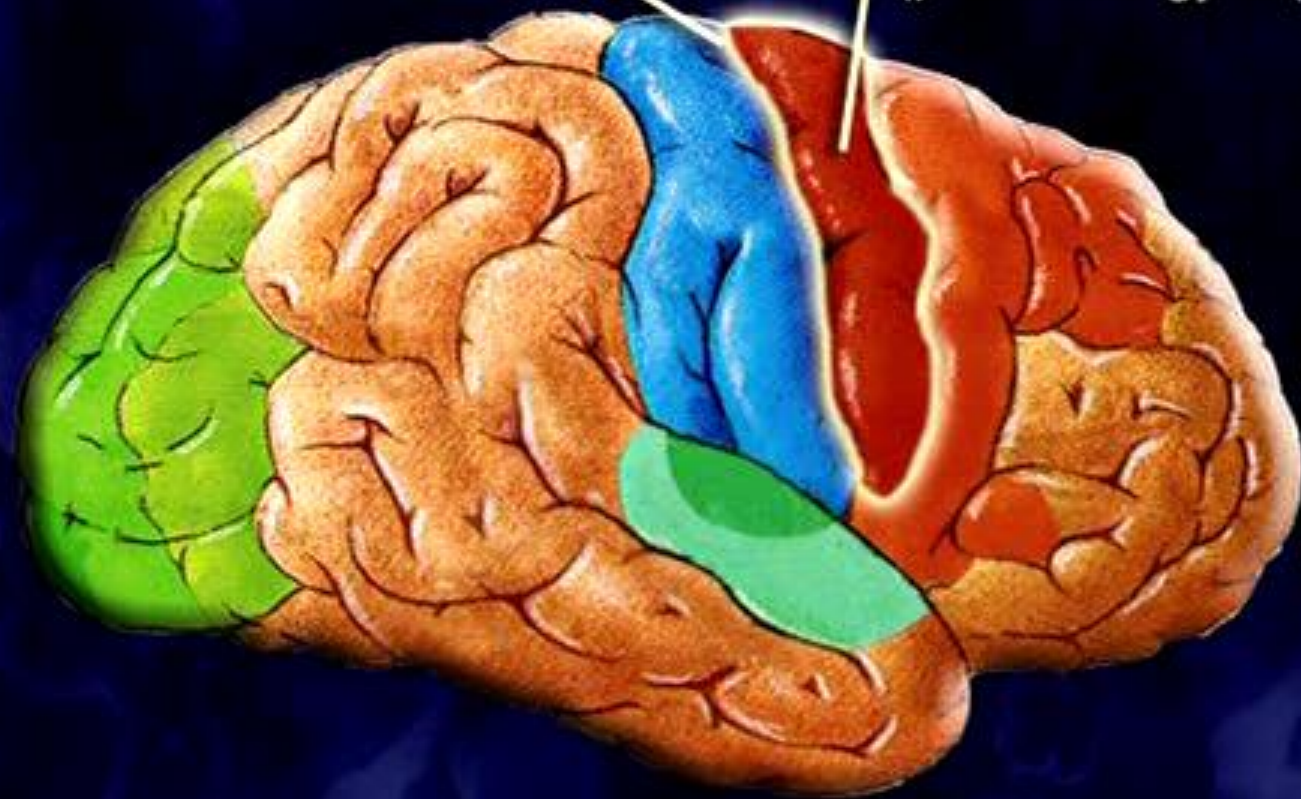
## Frontal lobe

**Somatomotor cortex,  
motor-speech, reasoning,  
problem-solving,  
motivation, personality,  
moral/social propriety**



Central sulcus

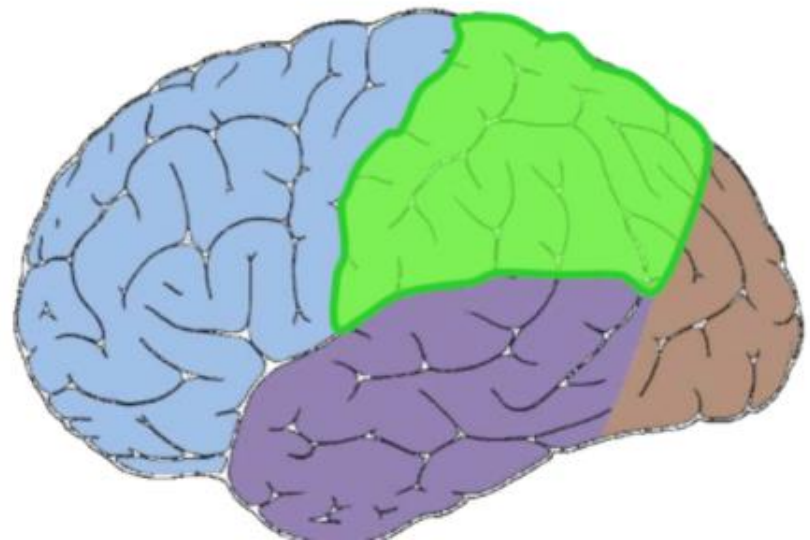
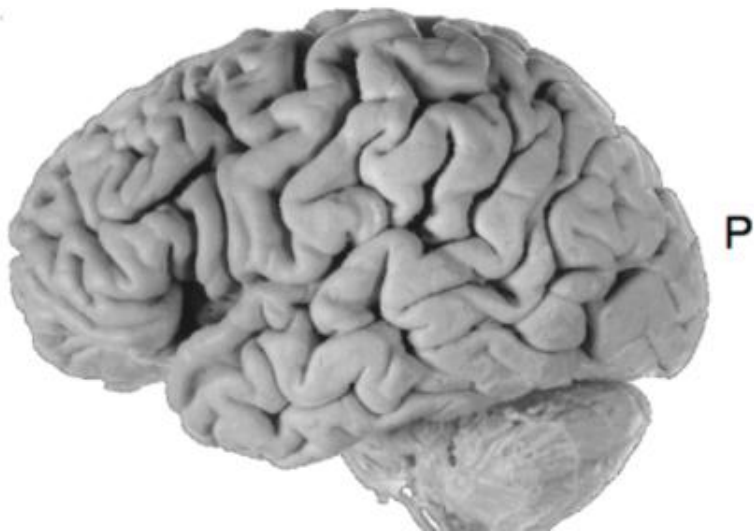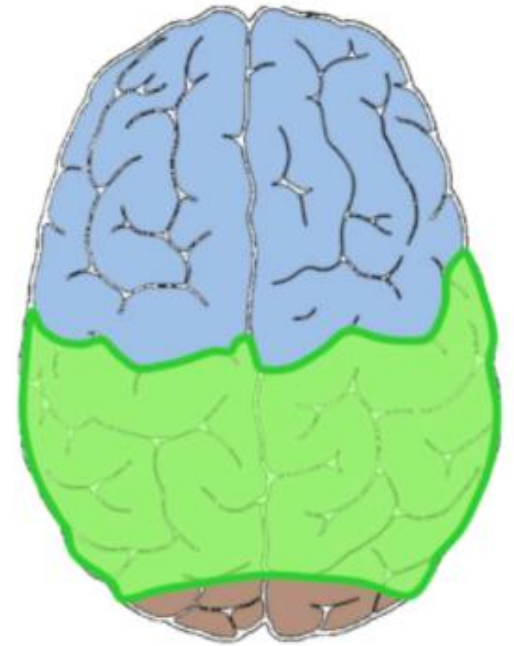
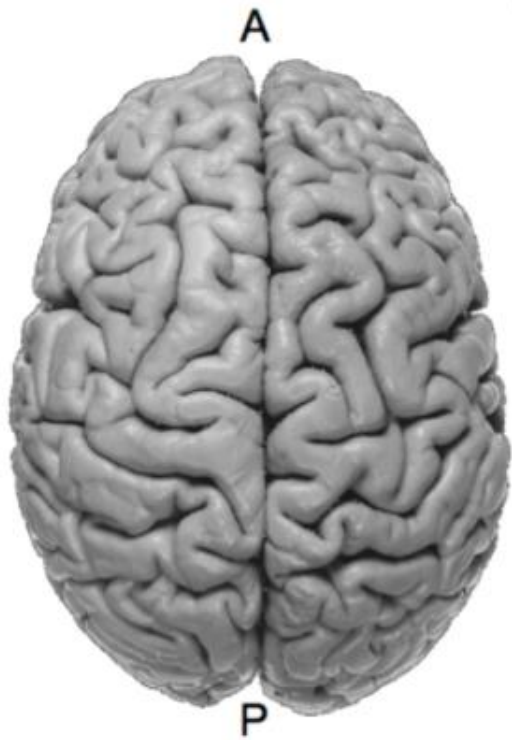PRIMARY MOTOR AREA  
(precentral gyrus)



# Cortical Lobes

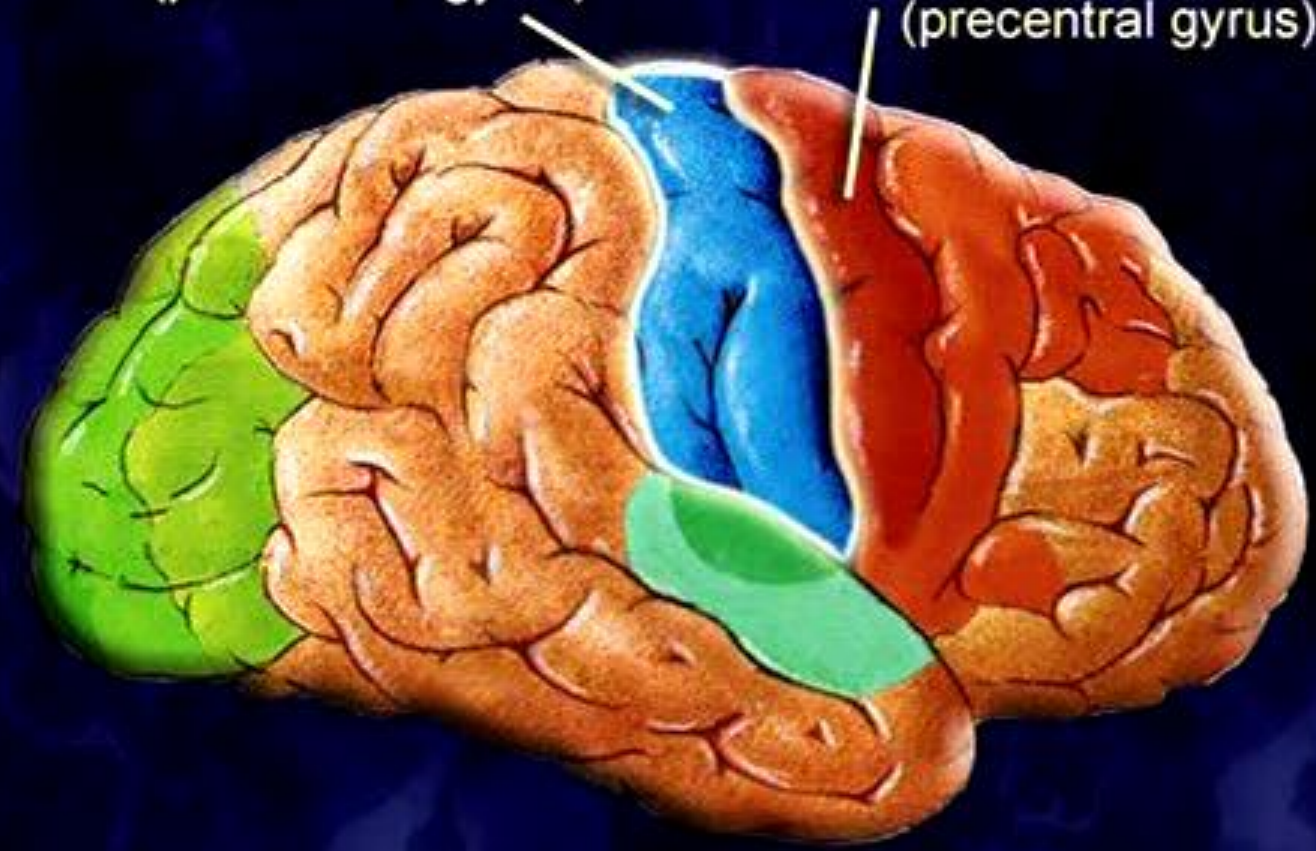
## Parietal lobe

**Somatosensory cortex,  
spatial awareness,  
receptive-speech**

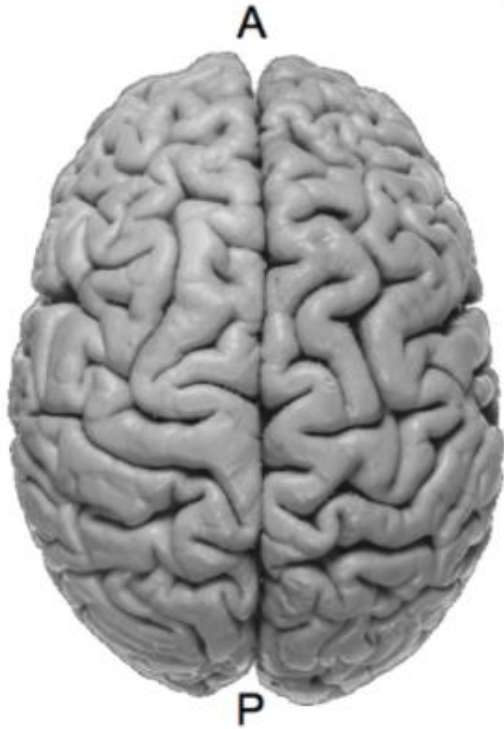

PRIMARY SOMATOSENSORY AREA  
(postcentral gyrus)

PRIMARY MOTOR AREA  
(precentral gyrus)

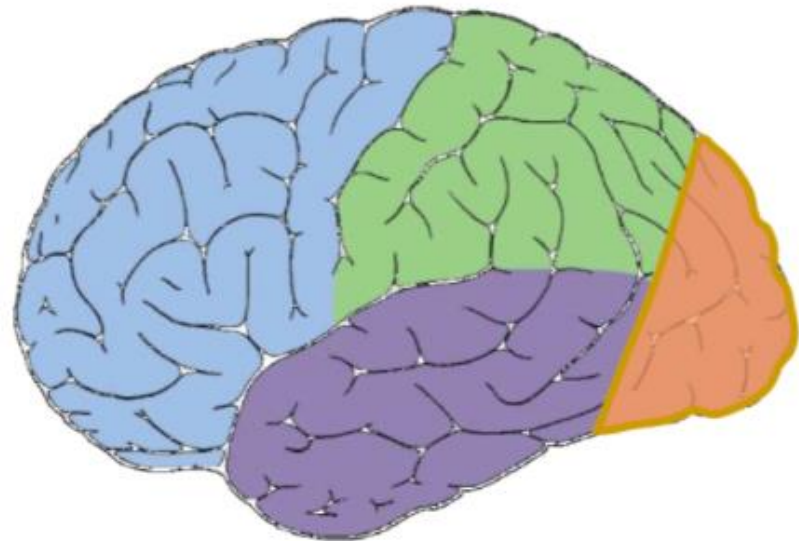
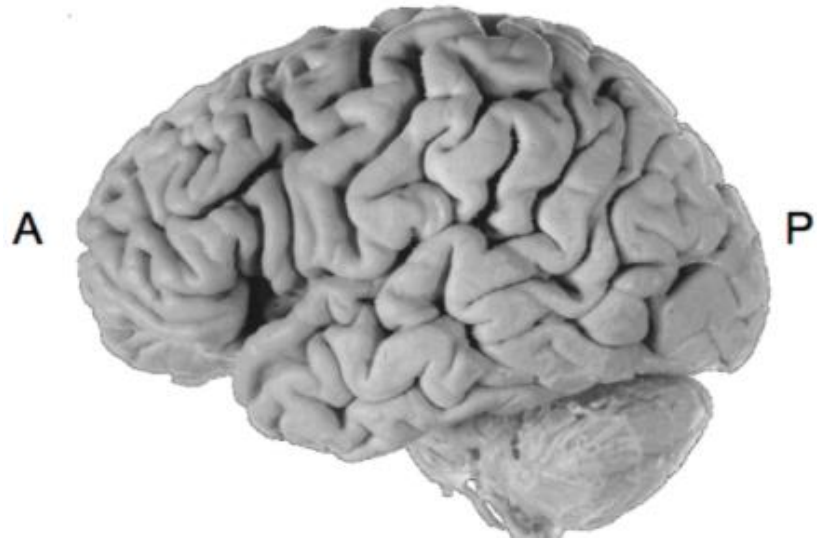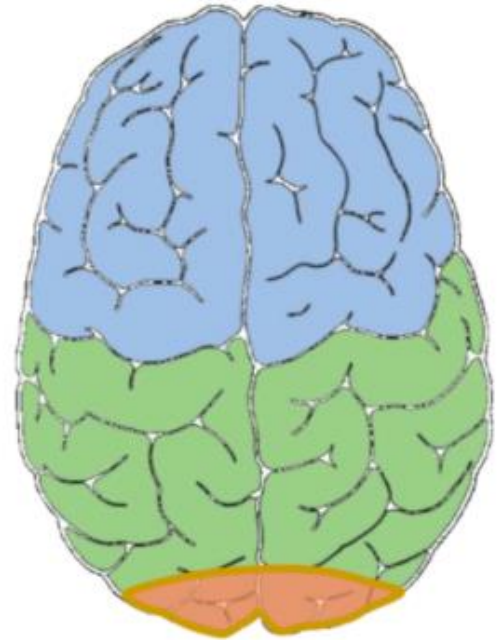


# Cortical Lobes

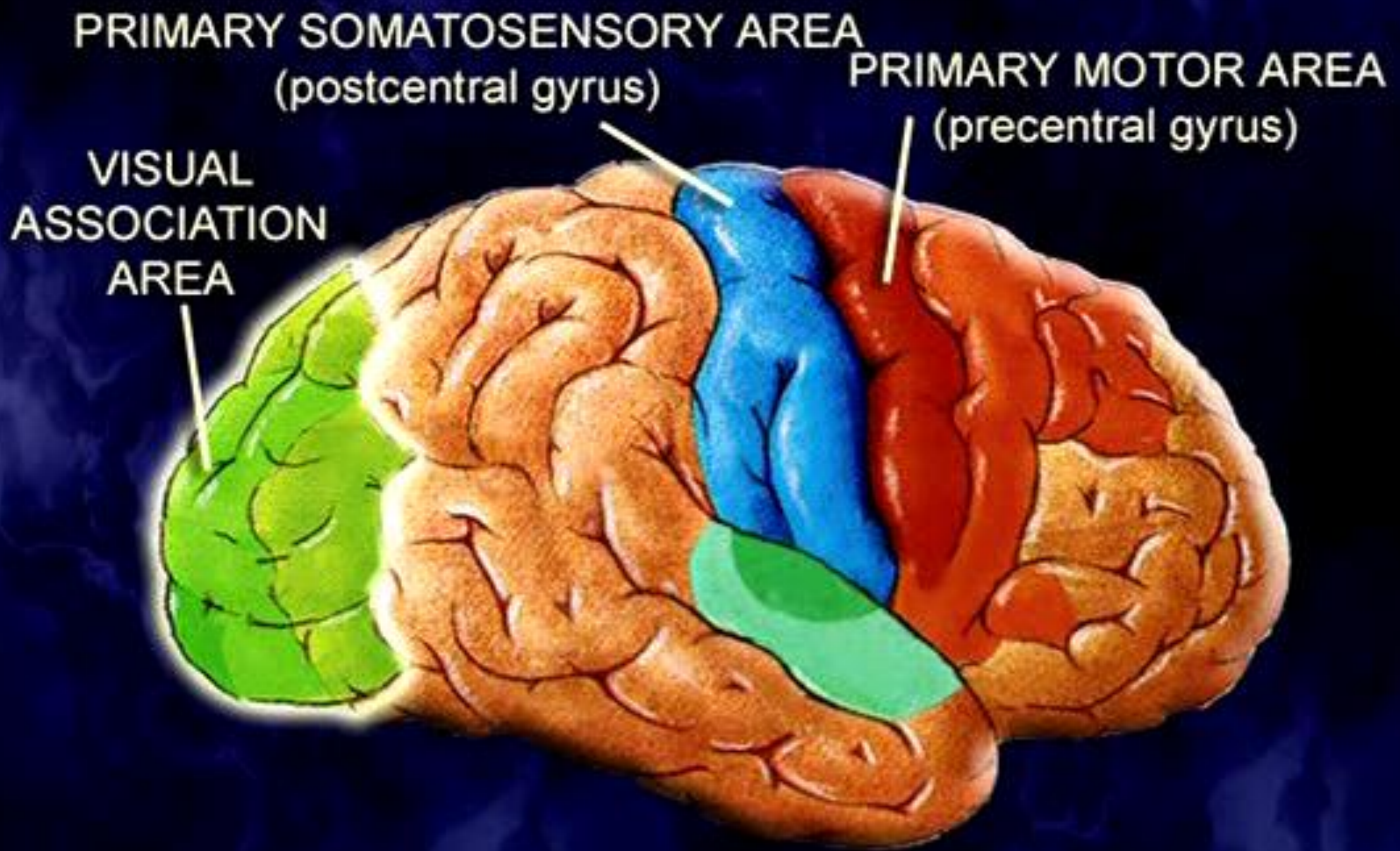


**Occipital lobe**

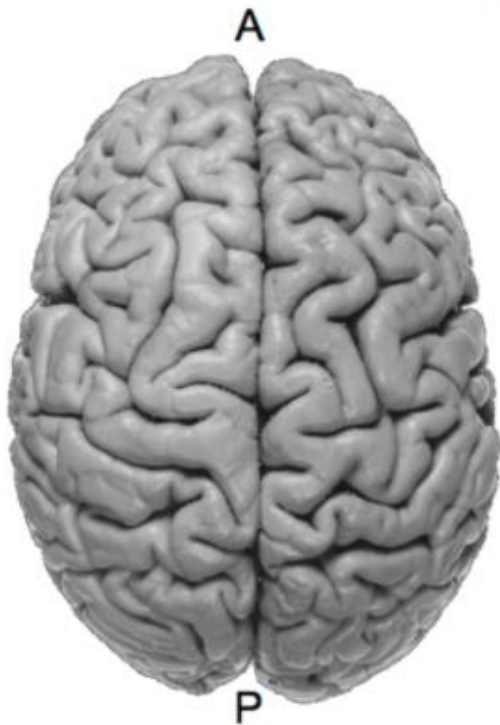**Vision**





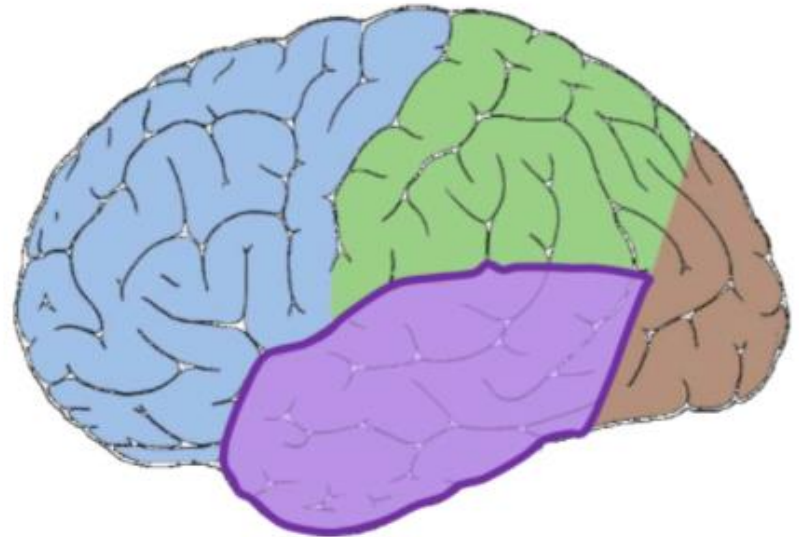
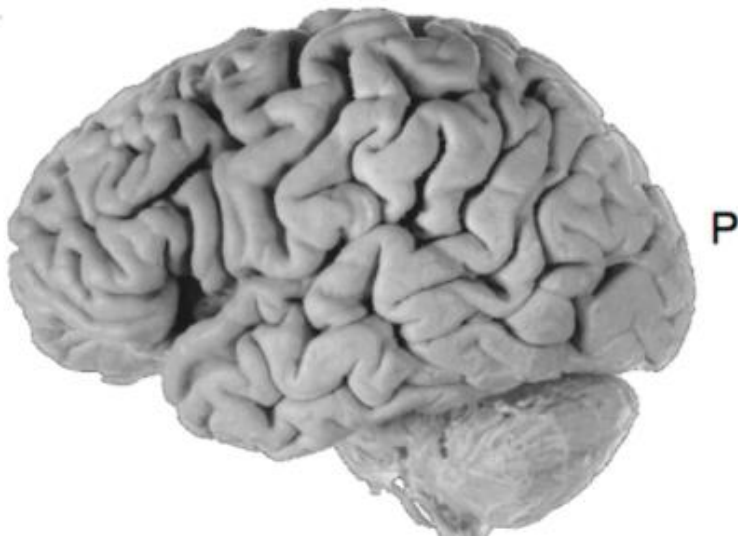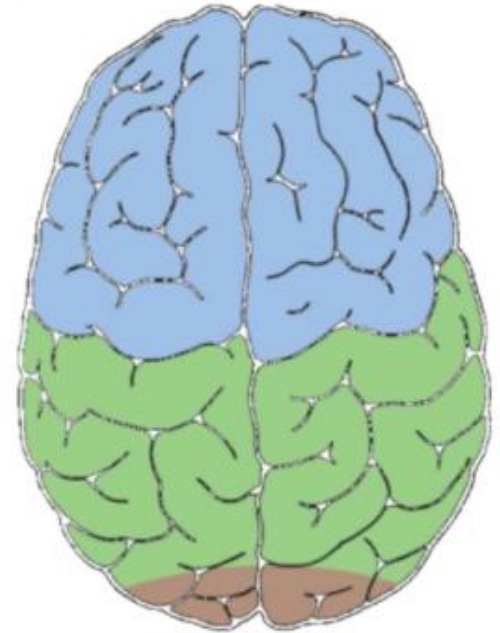


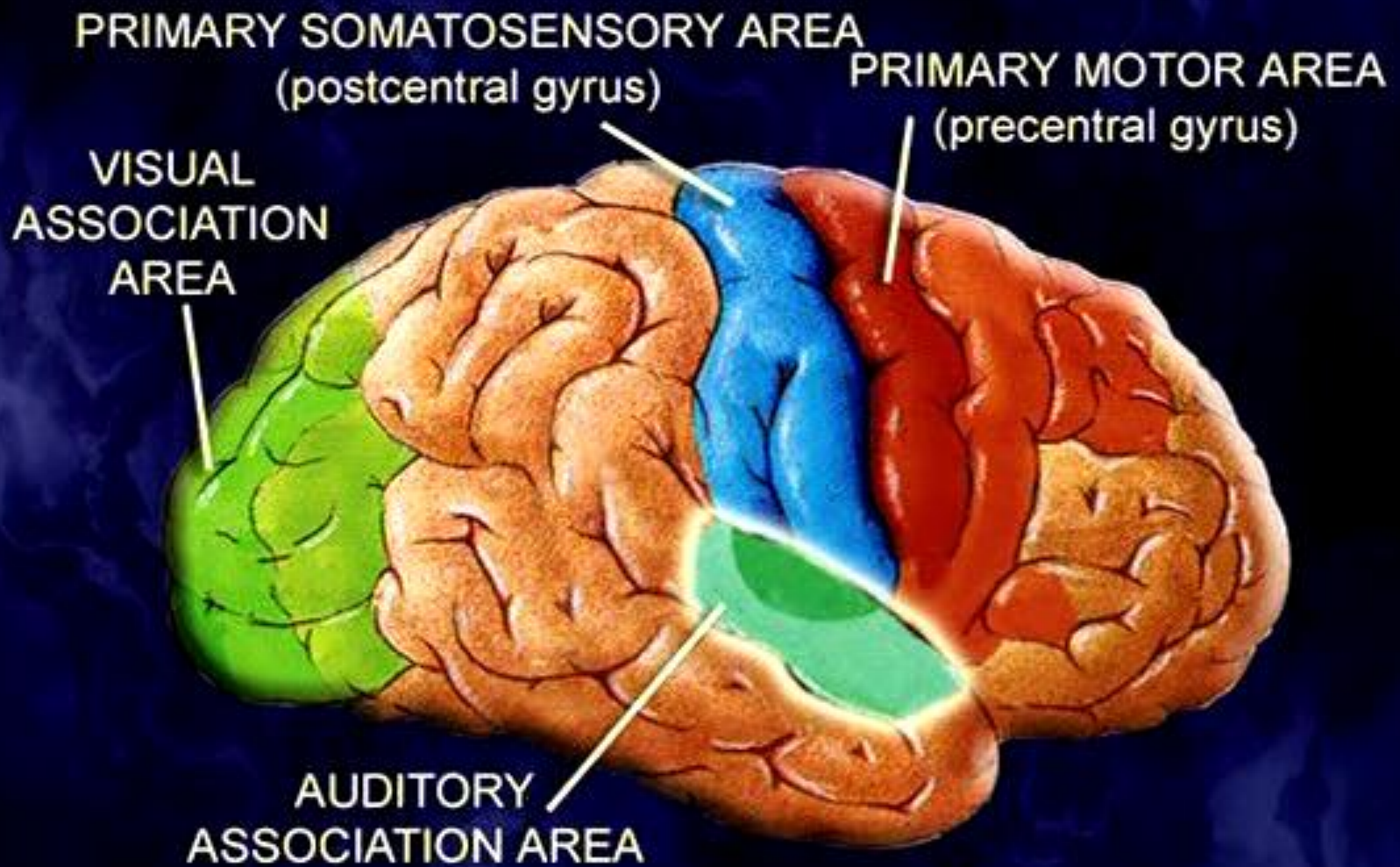
# Cortical Lobes

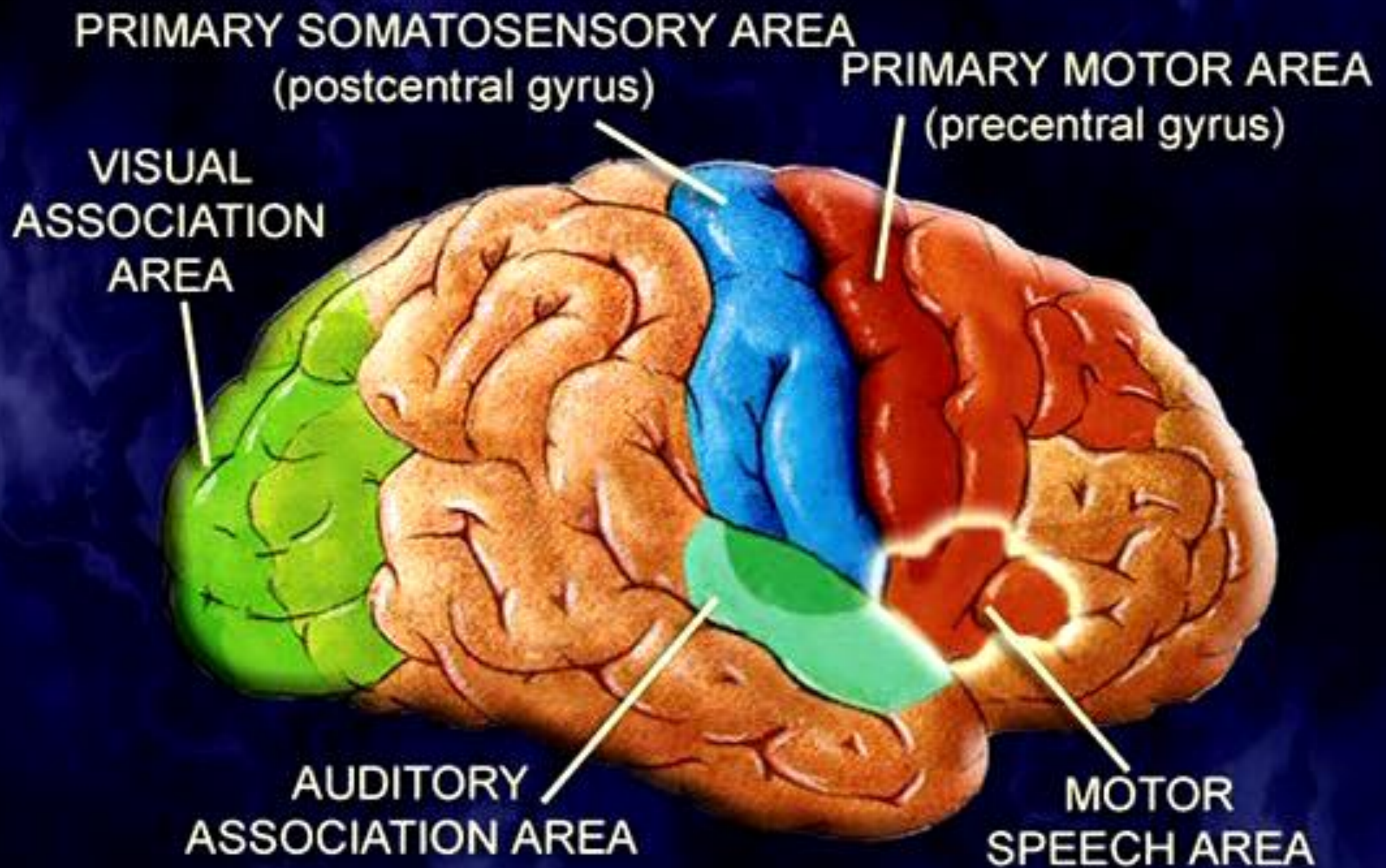


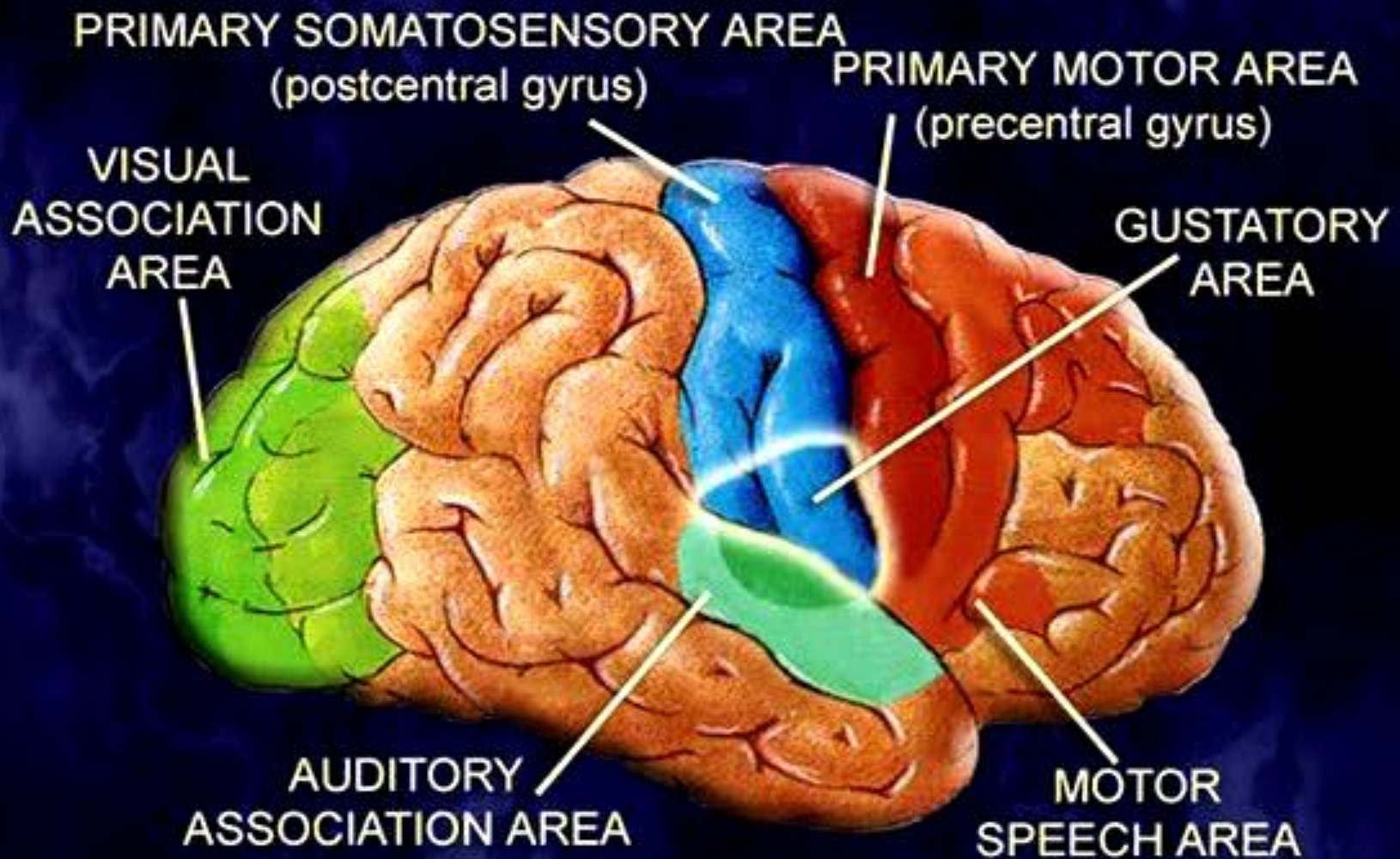
## Temporal lobe

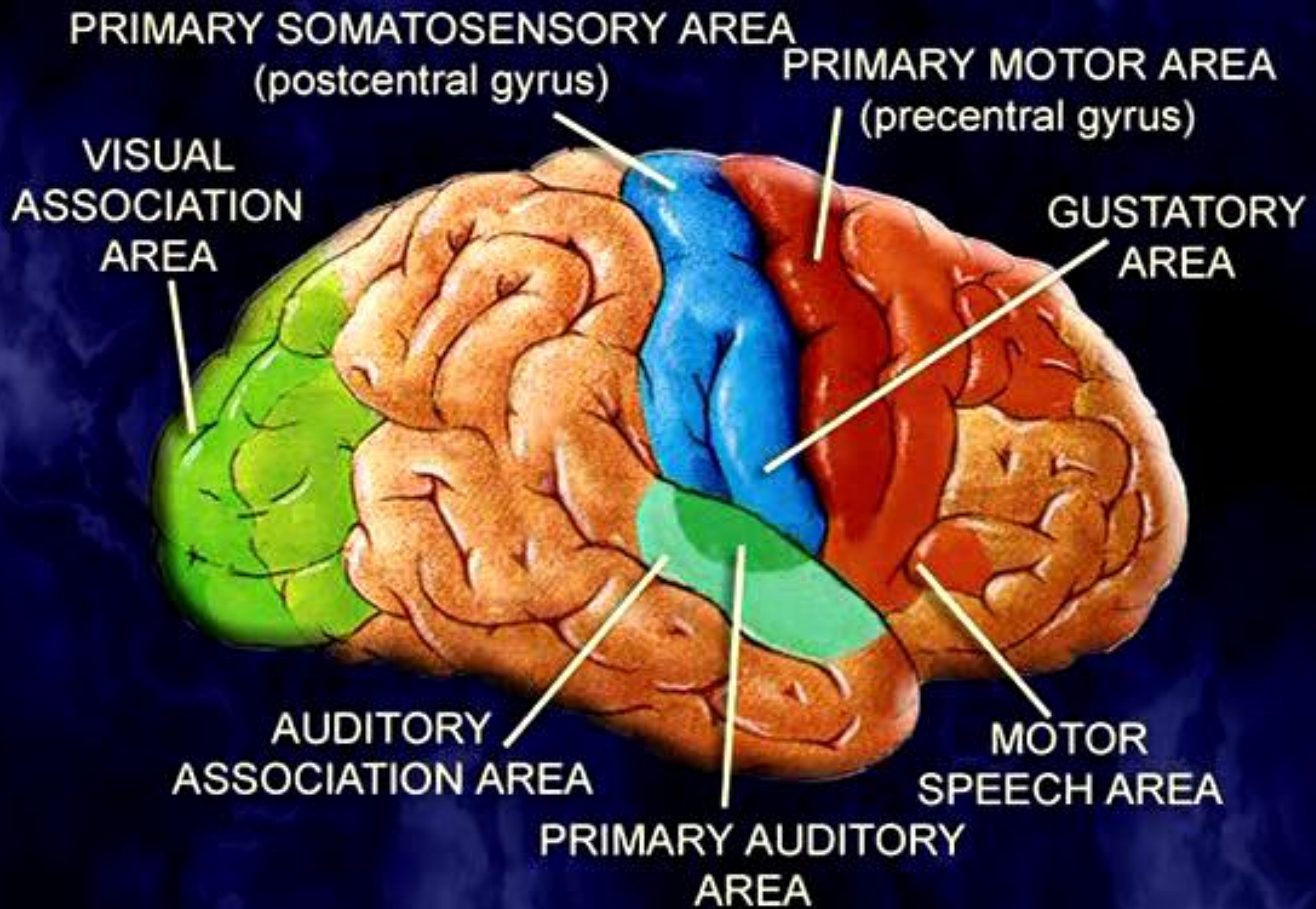
**Auditory cortex, limbic functions (emotion, memory formation, & learning)**





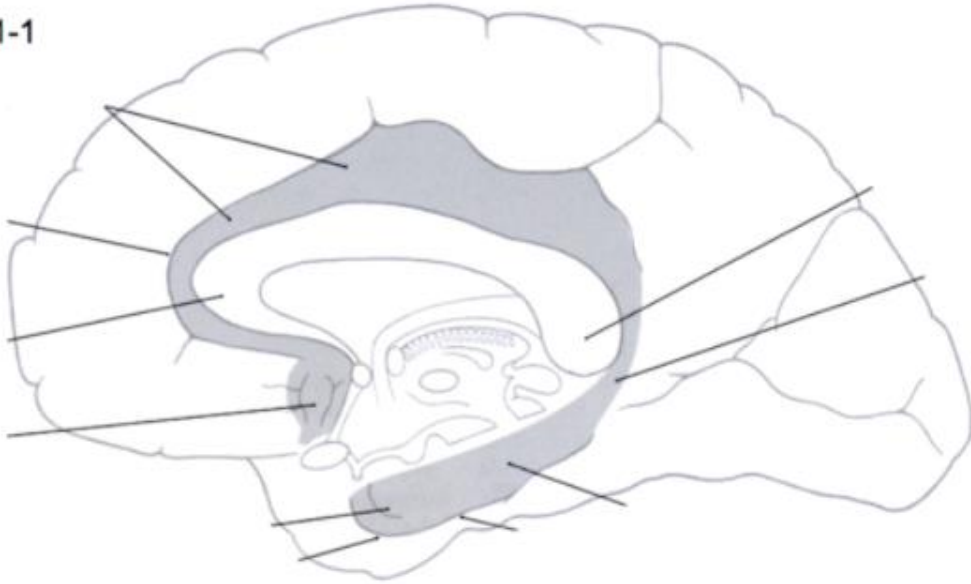






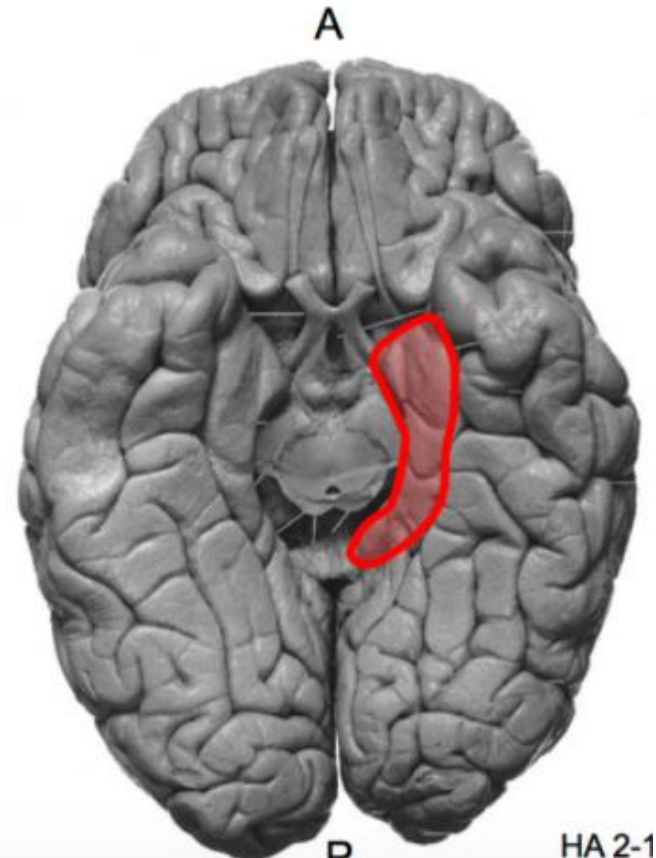
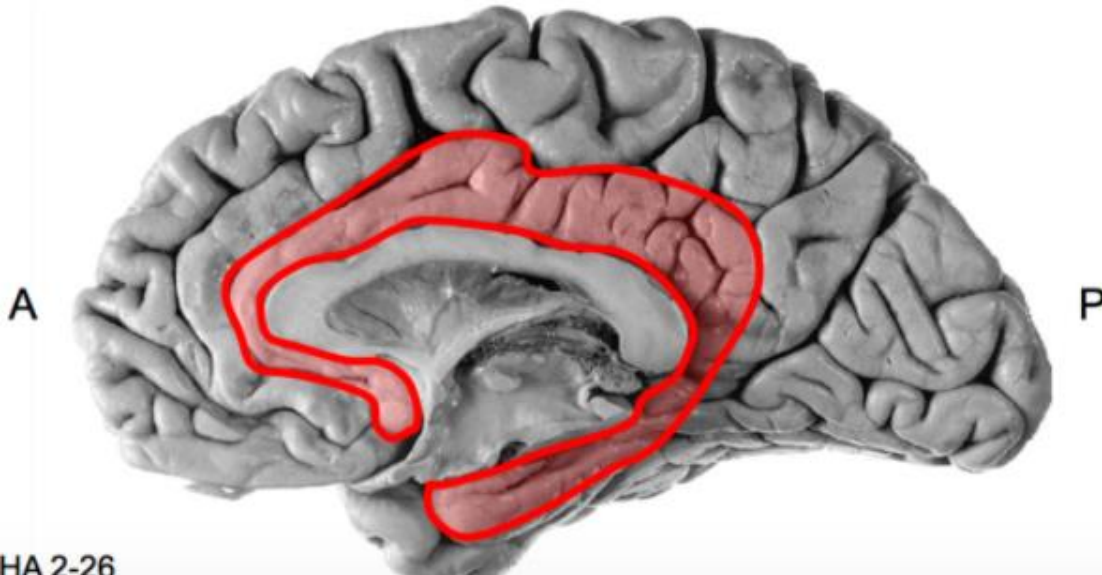
# Cortical Lobes

HT 31-1



**Limbic lobe**

**Emotion, memory formation, learning**



HA 2-26

HA 2-1

Side

Lateral ventricles

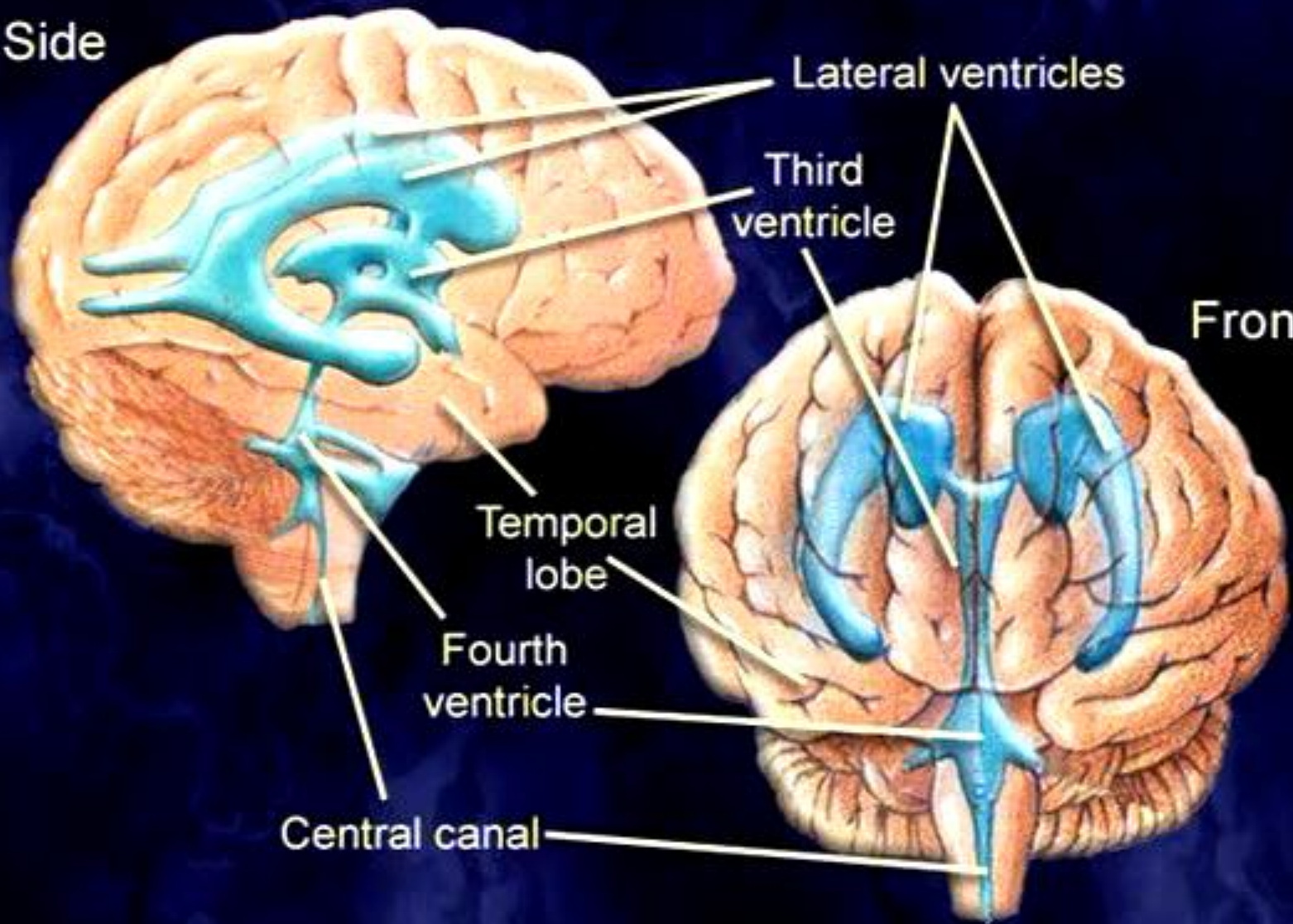
Third  
ventricle

Front

Temporal  
lobe

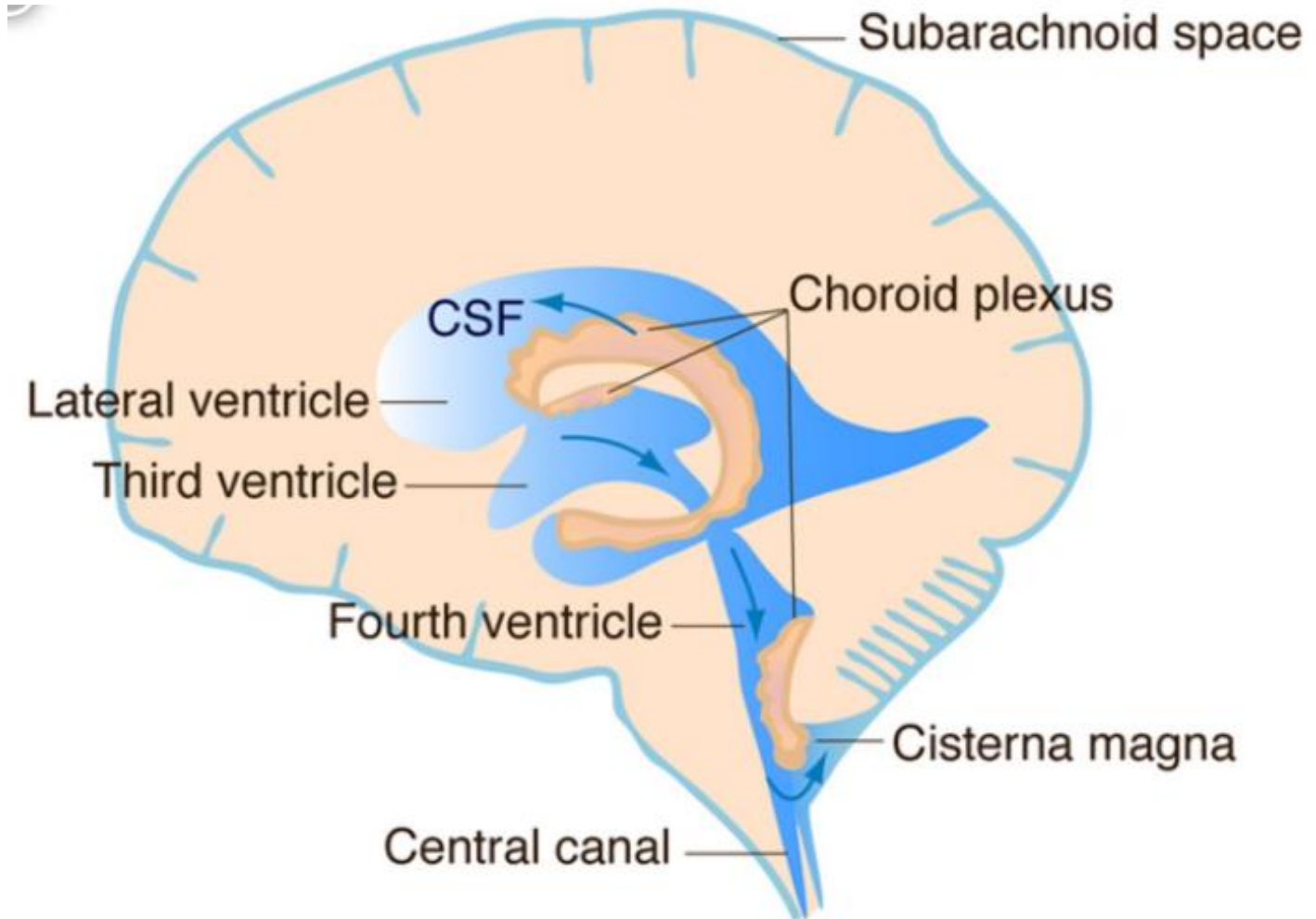
Fourth  
ventricle

Central canal

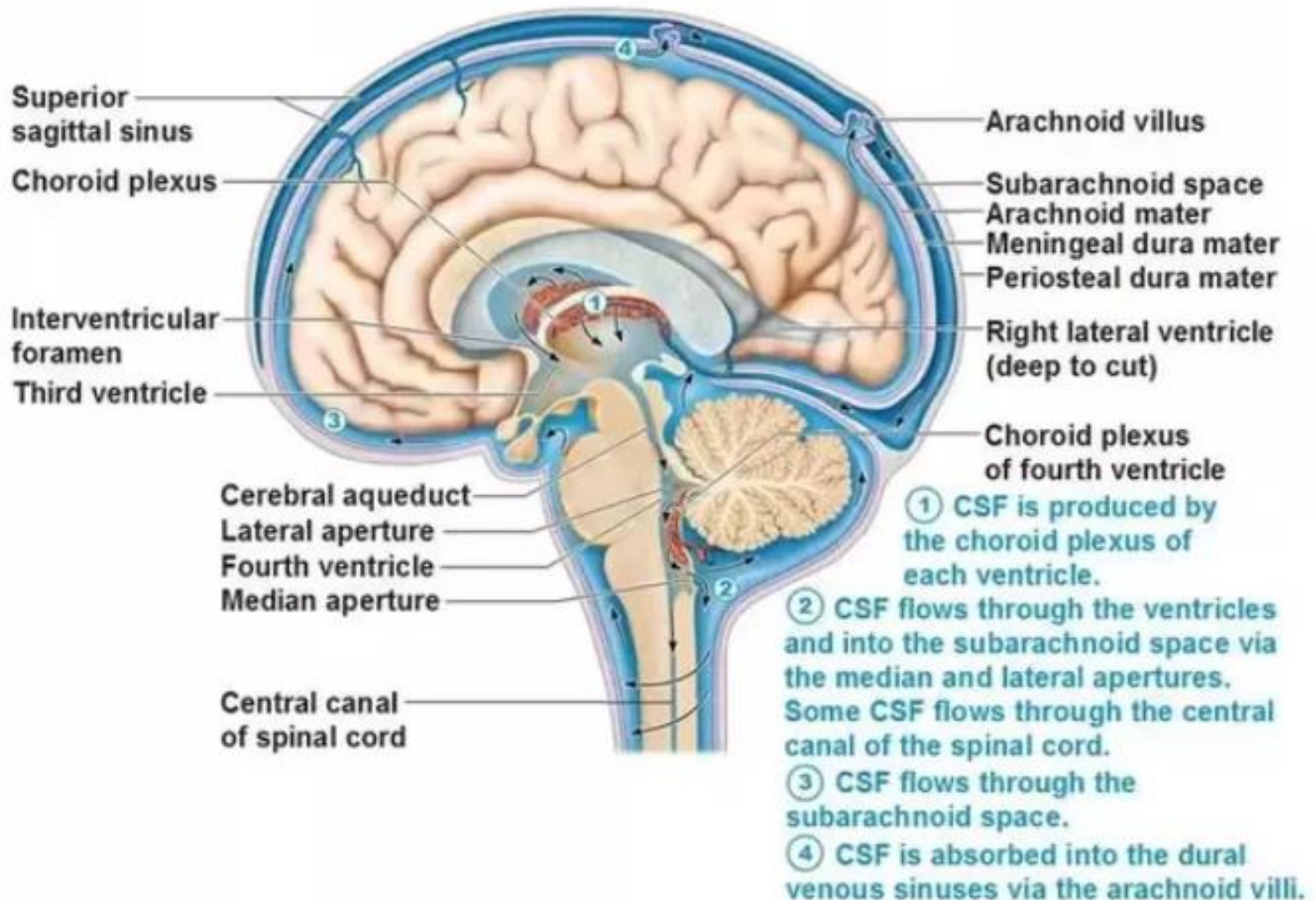




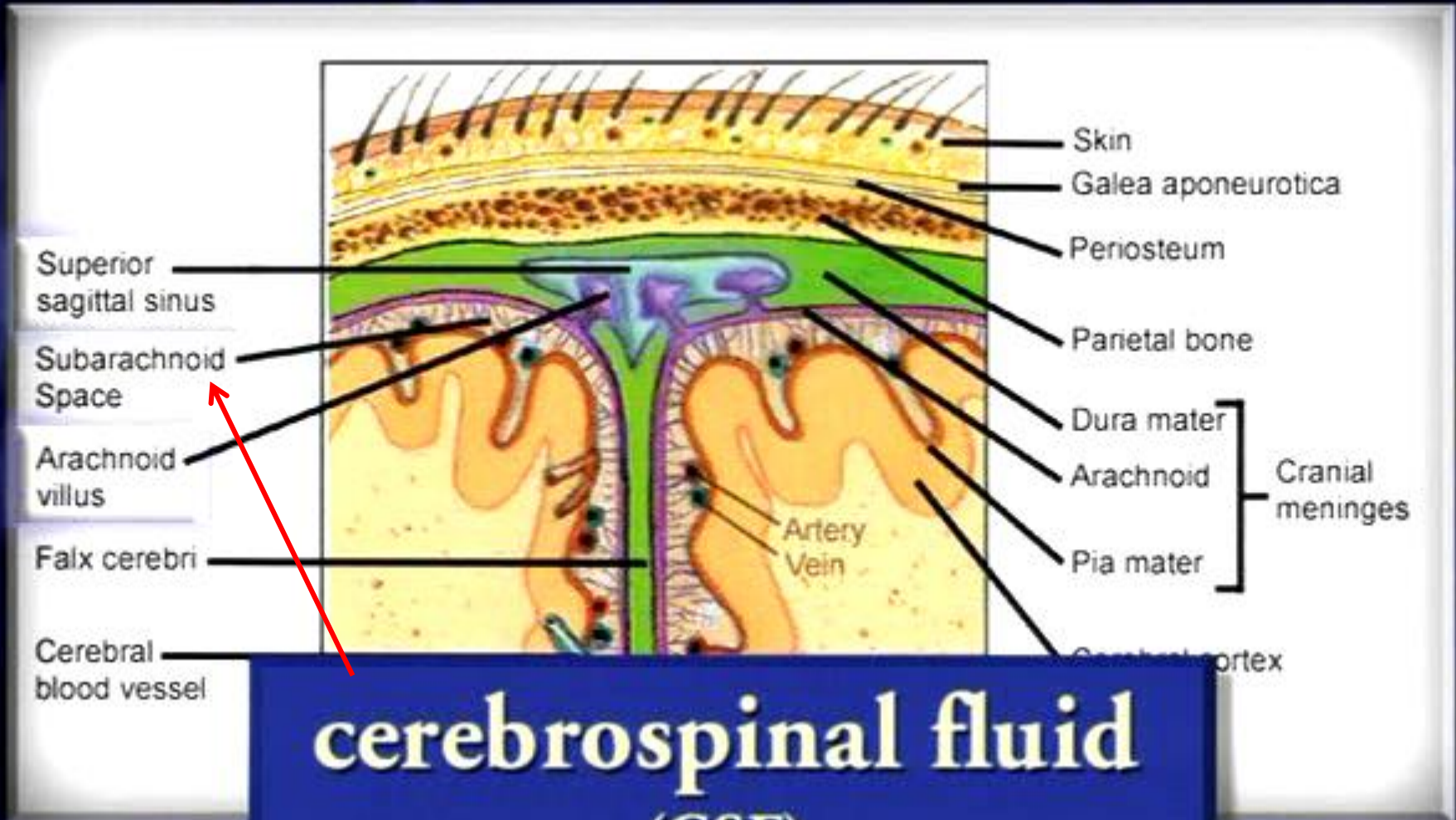
# The Choroid Plexus and Cerebrospinal Fluid



# Circulation of Cerebrospinal Fluid (CSF)



- **뇌척수액(cerebrospinal fluid, CSF):** 뇌 충격에 대한 완충작용을 하는 액체
  - CSF는 뇌실과 척수 중앙관을 따라 그리고 뇌척수막 사이 공간을 따라 뇌와 척수의 전체 표면을 적시며 순환
  - 신경세포들과 뇌를 둘러싸고 있는 간질액(CSF) 사이의 물질교환
  - 충격-흡수 액체로 작용하여 머리가 충격을 받았을 때 뇌가 딱딱한 두개골 내부에 부딪치는 것을 방지하는 쿠션 역할
  - CSF는 뇌조직과 거의 같은 밀도를 갖고 있으므로 뇌는 실질적으로 이 특수 액체 환경에 떠 있는 셈



Superior sagittal sinus

Subarachnoid Space

Arachnoid villus

Falx cerebri

Cerebral blood vessel

Skin

Galea aponeurotica

Periosteum

Parietal bone

Dura mater

Arachnoid

Pia mater

Cranial meninges

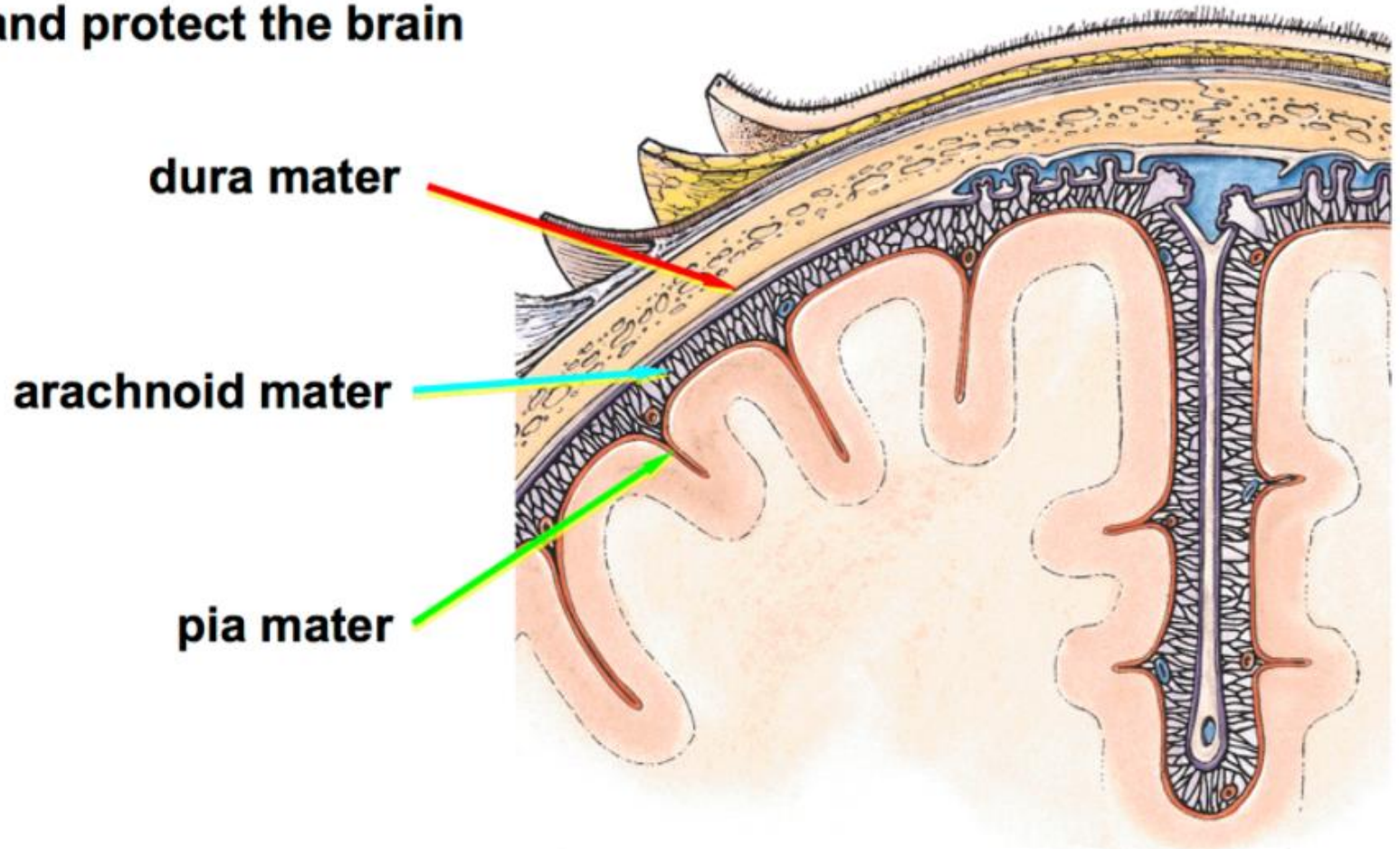
Artery  
Vein

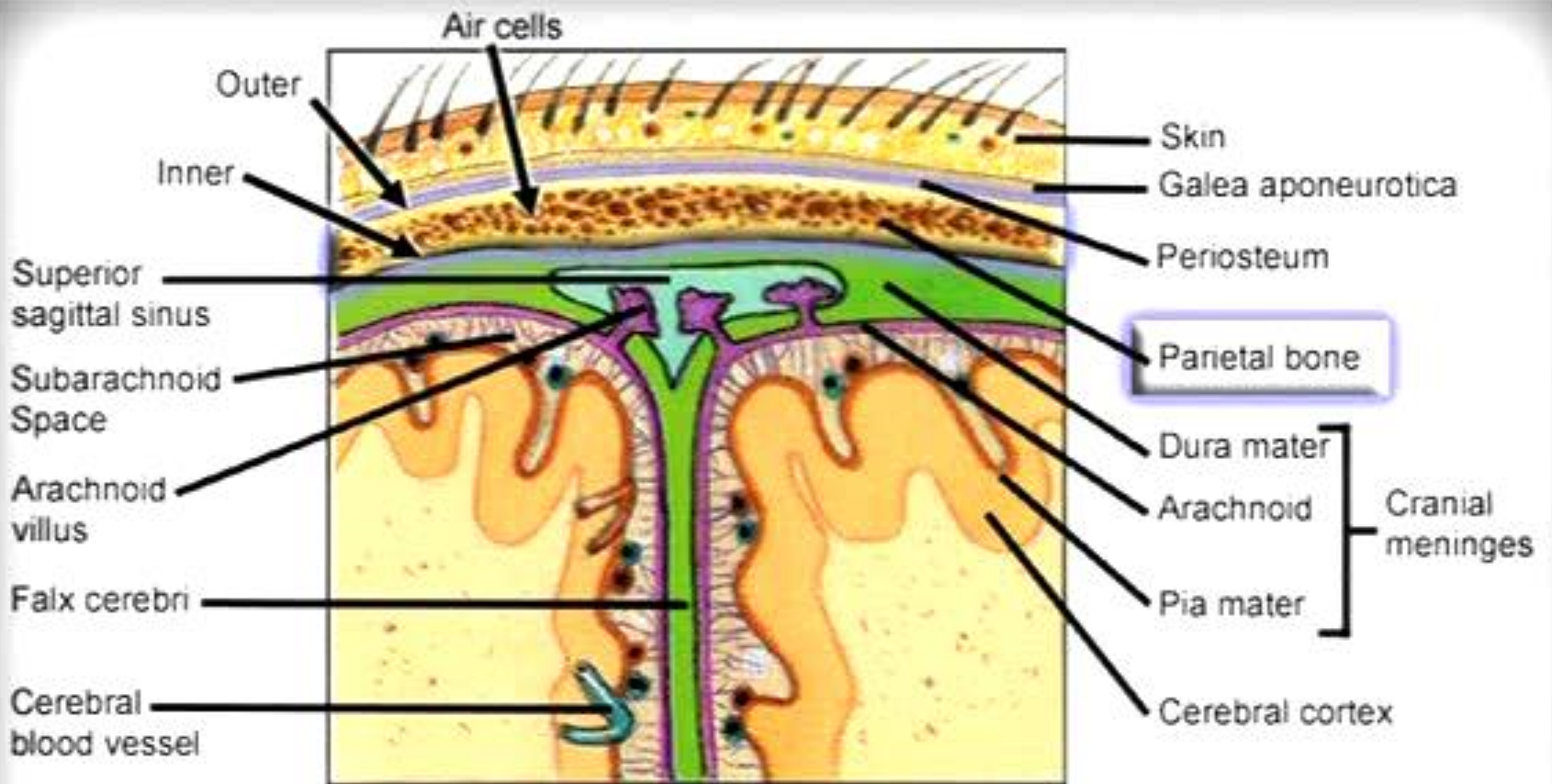
Cerebral cortex

# cerebrospinal fluid (CSF)

# Cranial Meninges

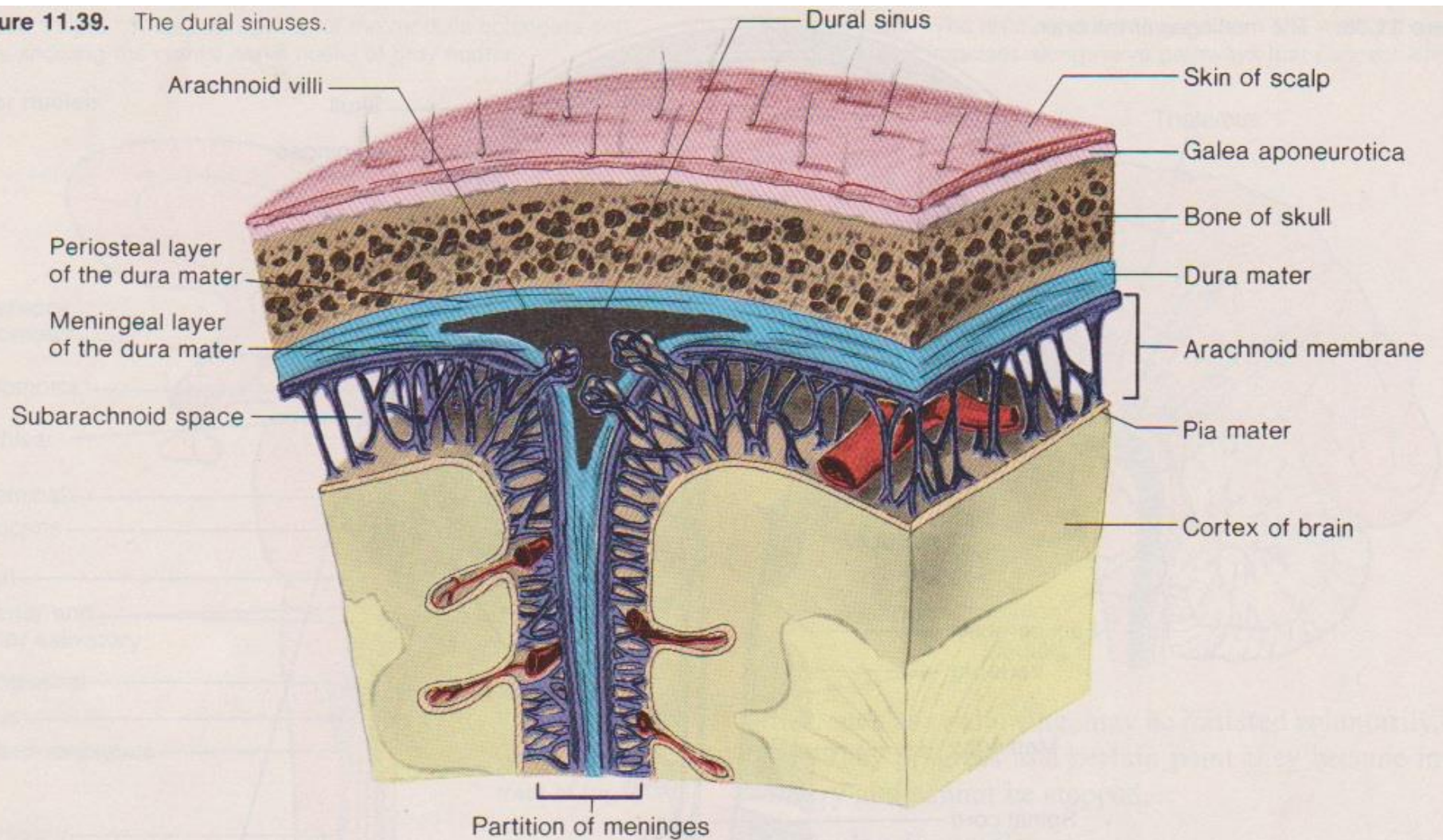
The cranial meninges are a series of connective tissue layers that cover and protect the brain





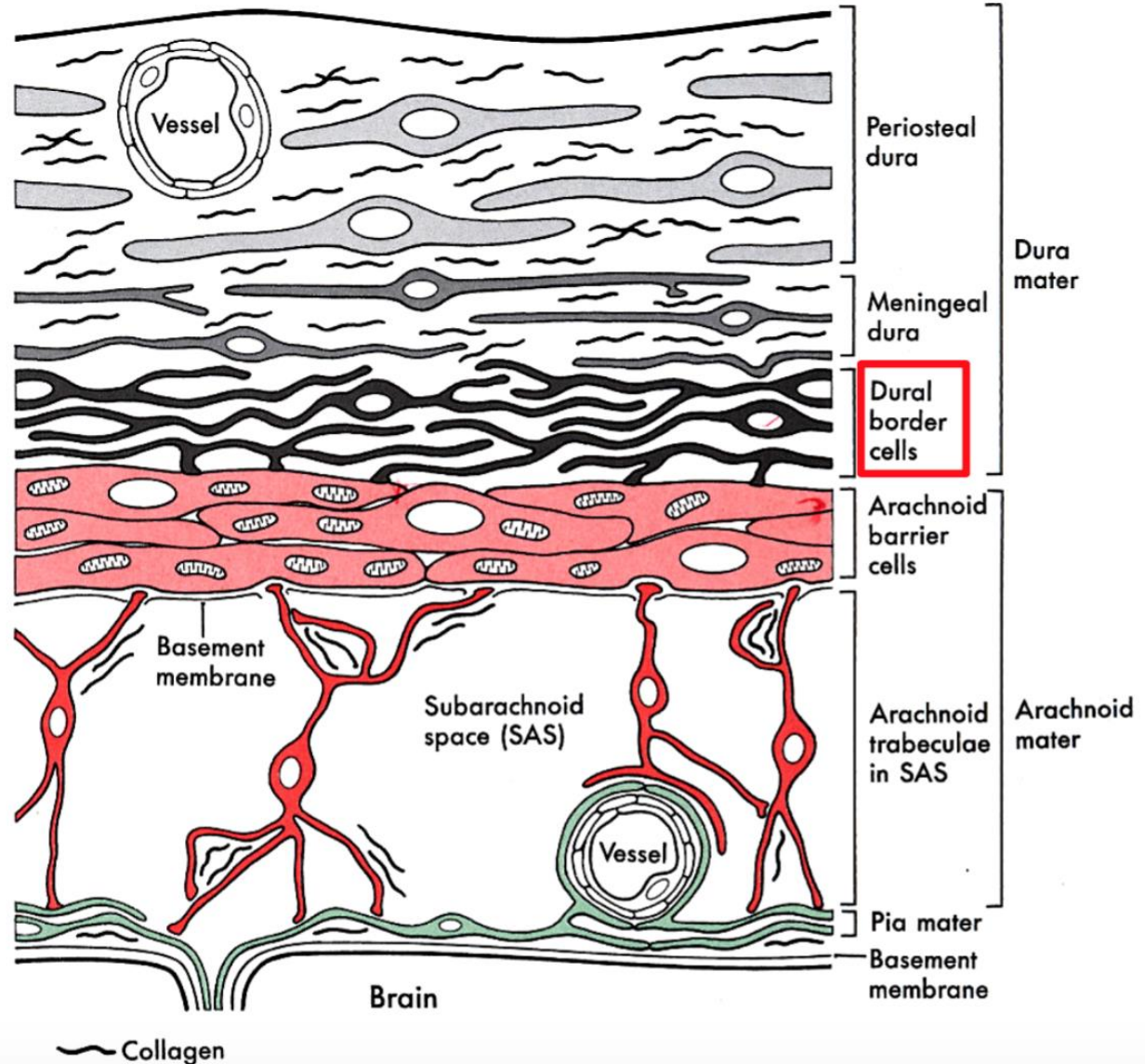
Frontal section

**Figure 11.39.** The dural sinuses.



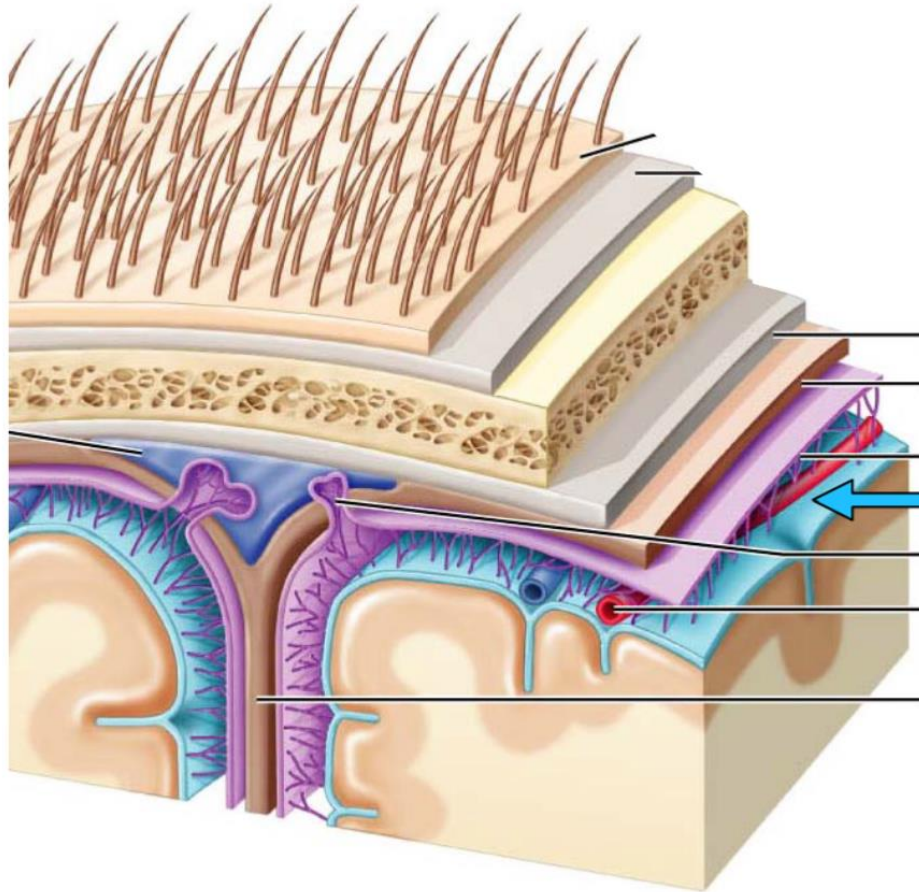
# Dura Mater

The deepest layer of the dura mater is composed of flattened fibroblastic cells that form the **dural border** cell layer. This layer is an area of structural weakness.





# Pia Mater



## **pia mater**

- thin, innermost layer of the meninges
- adheres directly to the surface of the brain and follows all of its contours
- forms a short “sleeve” around small vessels penetrating into the brain

# Arterial Supply of the Brain

## anterior circulation

internal carotid artery

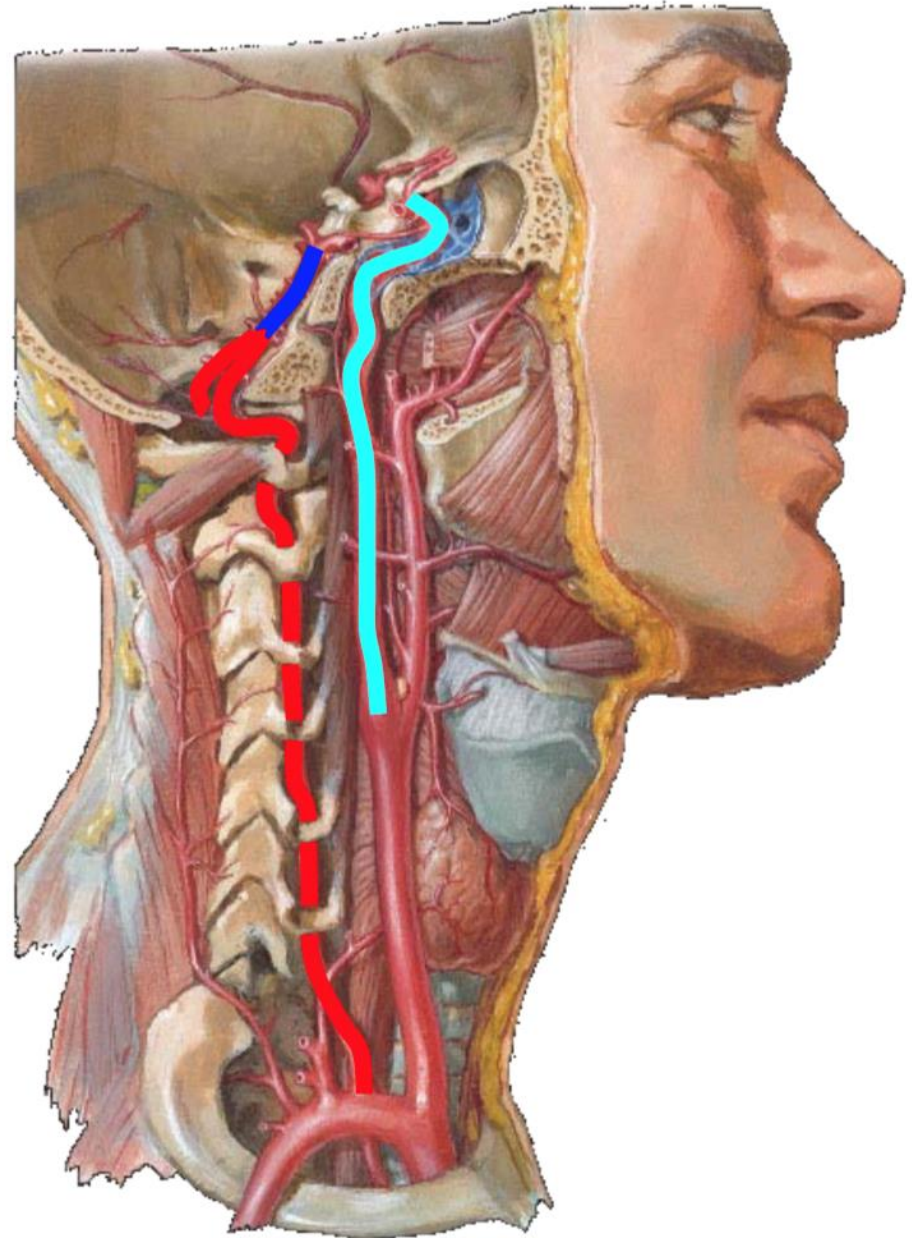


## posterior circulation

vertebral artery



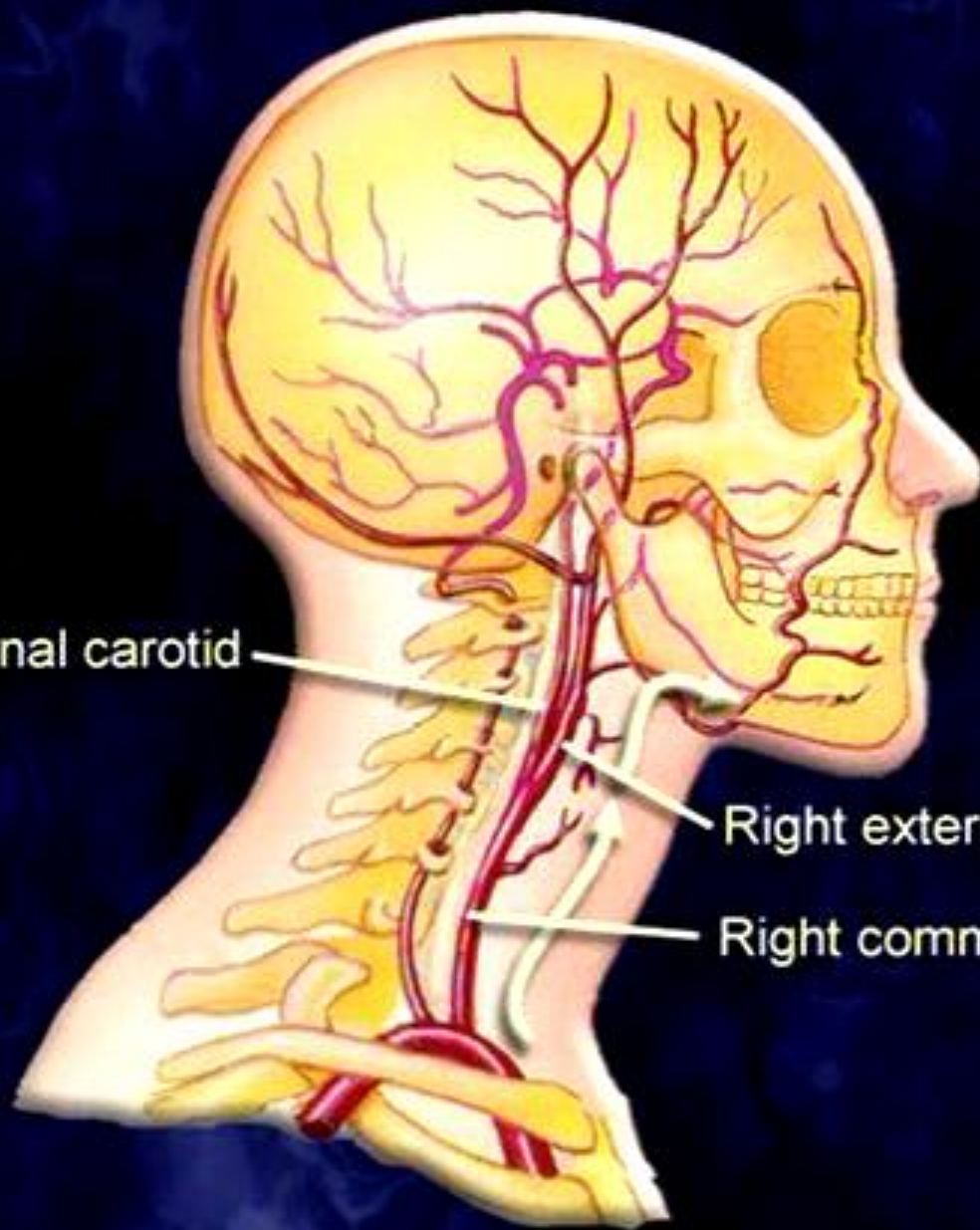
right & left vertebral  
arteries merge to form  
the basilar artery



Right internal carotid

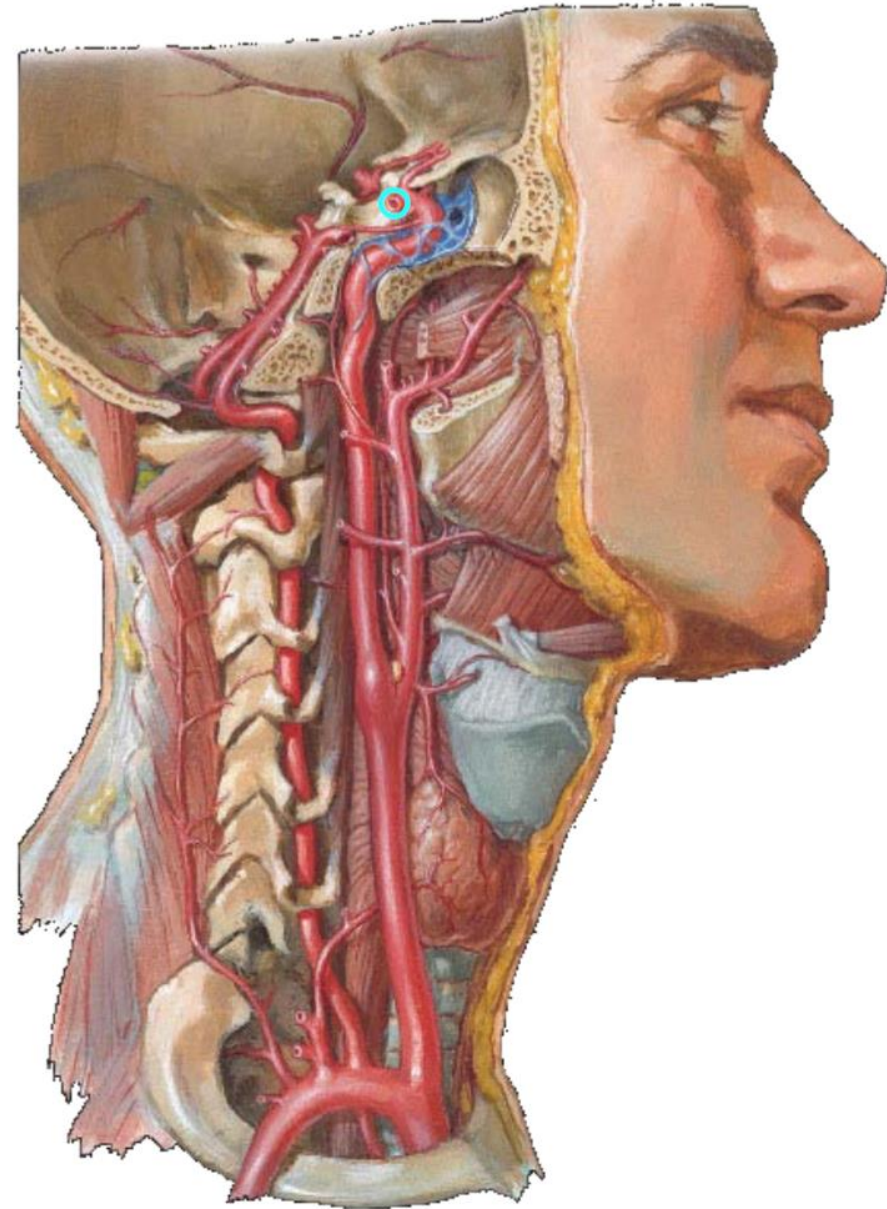
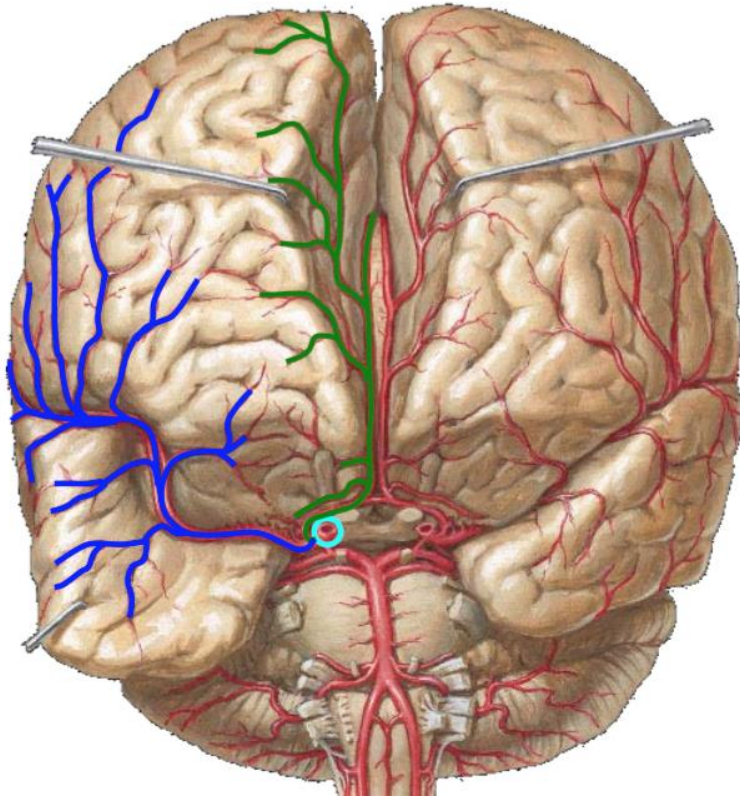
Right external carotid

Right common carotid



# Anterior Circulation

- **Internal carotid system**
  - Each **internal carotid artery** bifurcates into **middle** and **anterior** cerebral arteries



# Posterior Circulation

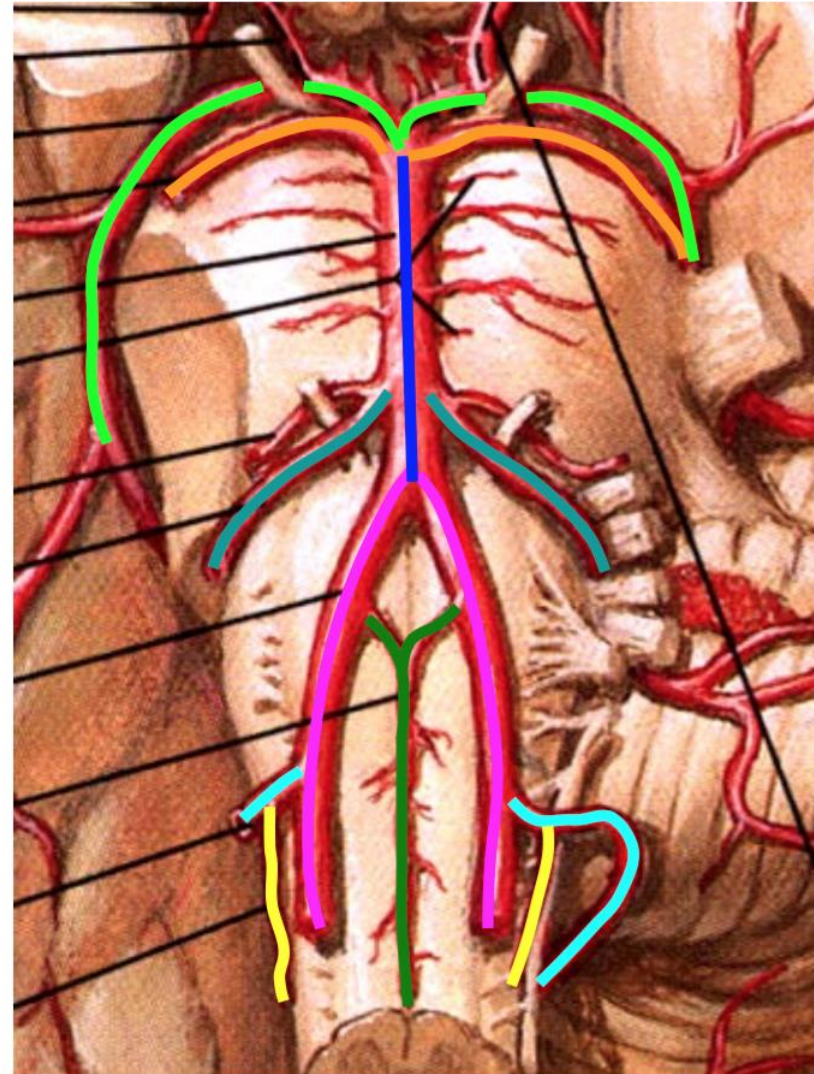
## Vertebral-basilar system

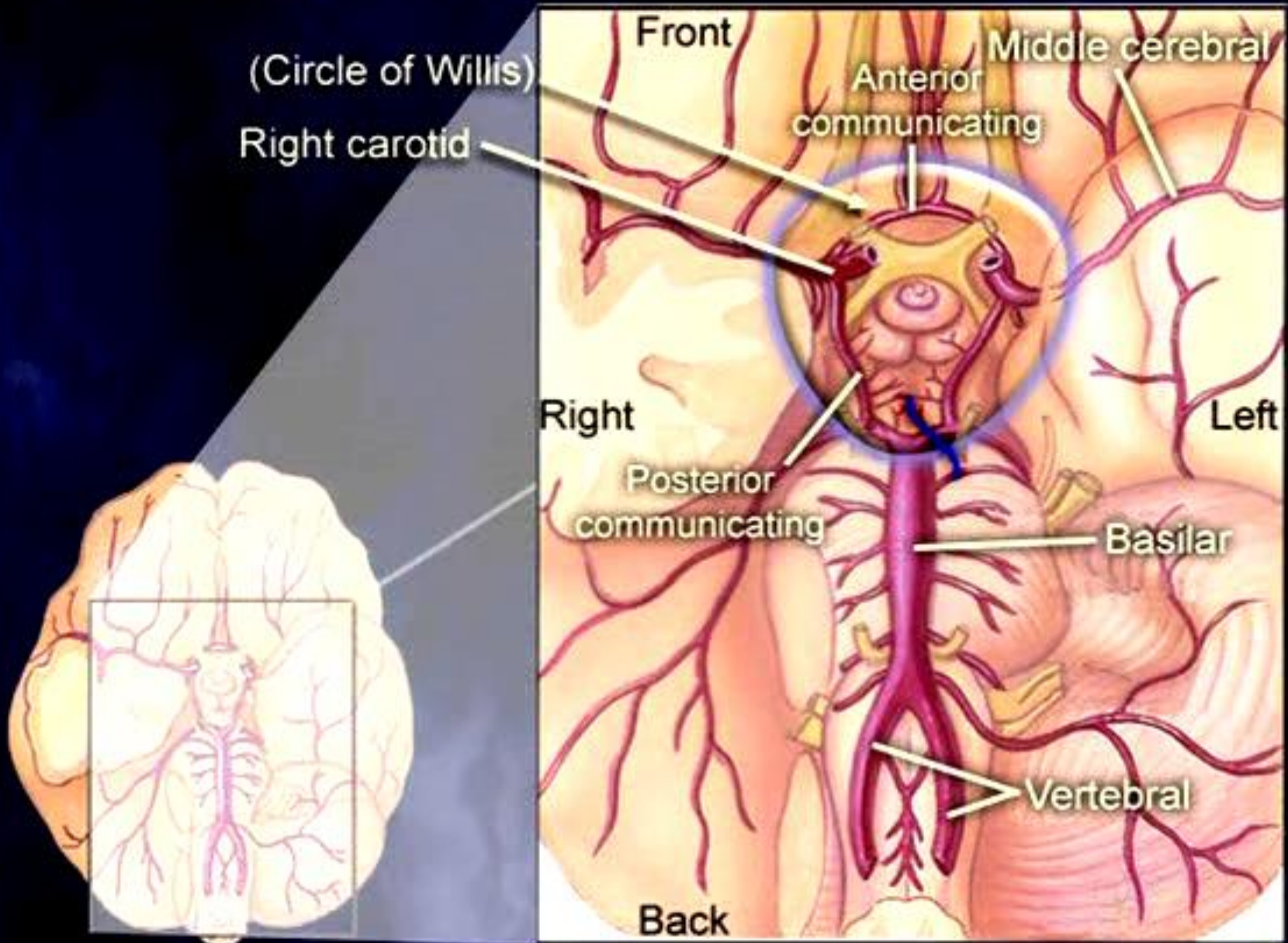
### – Vertebral arteries

- Posterior inferior cerebellar arteries (PICA)
- Posterior spinal arteries
- Anterior spinal artery

### – Basilar artery

- Anterior inferior cerebellar arteries (AICA)
- Superior cerebellar arteries
- Basilar artery ends by bifurcating into right and left posterior cerebral arteries

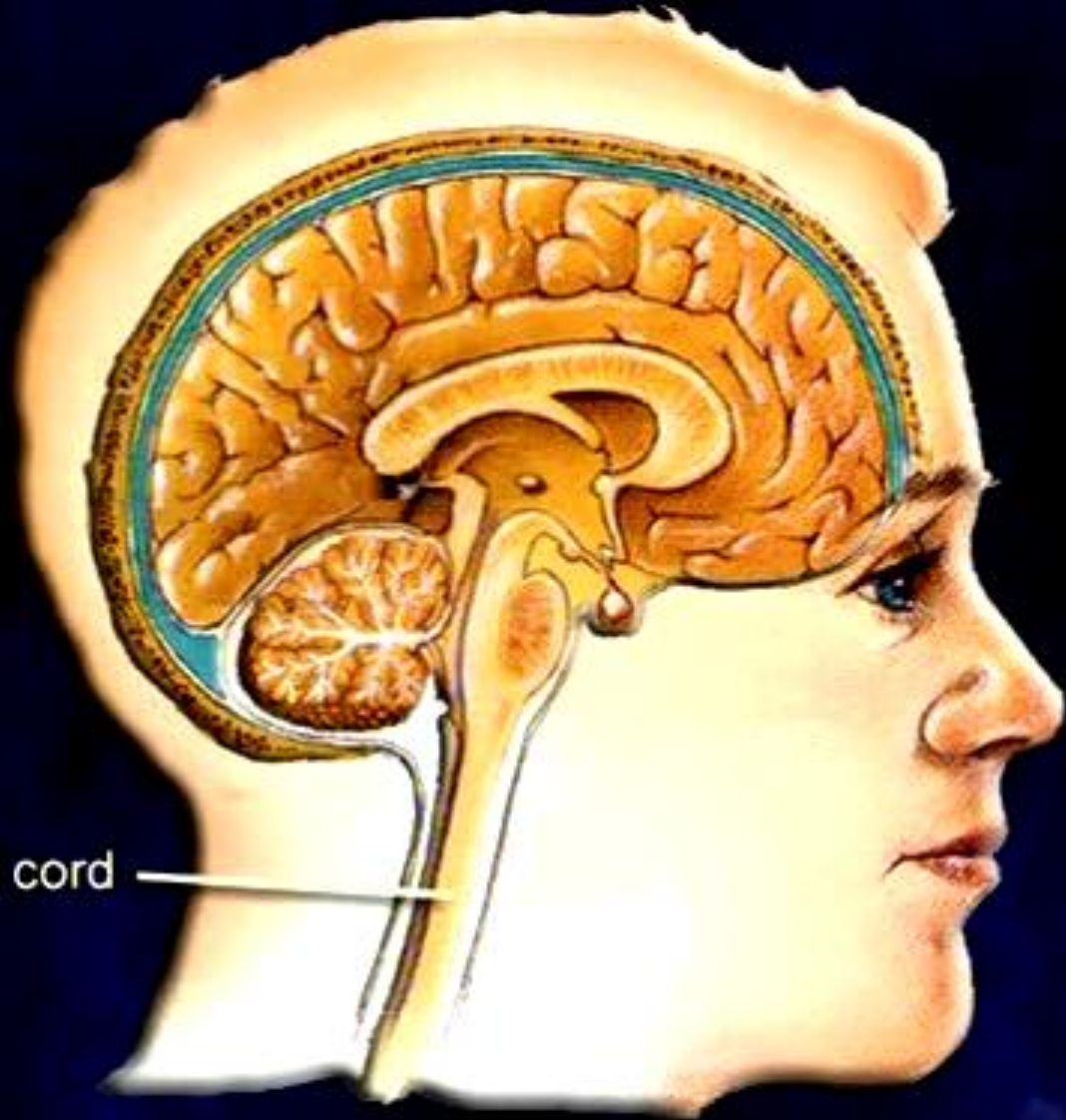




# 중추신경계(CNS): 개요

- 뇌와 척수로 구성(뇌에 약 1000억 개의 뉴런들)
- CNS의 작용:
  - (1) 신경 작용에 의해 잠재의식적으로 신체 내부 환경을 조절
  - (2) 감정을 느끼고,
  - (3) 의식적인 움직임의 조절
  - (4) 신체와 주변 상황을 인식
  - (5) 생각, 기억과 같은 고등 인지 작용

Spinal cord





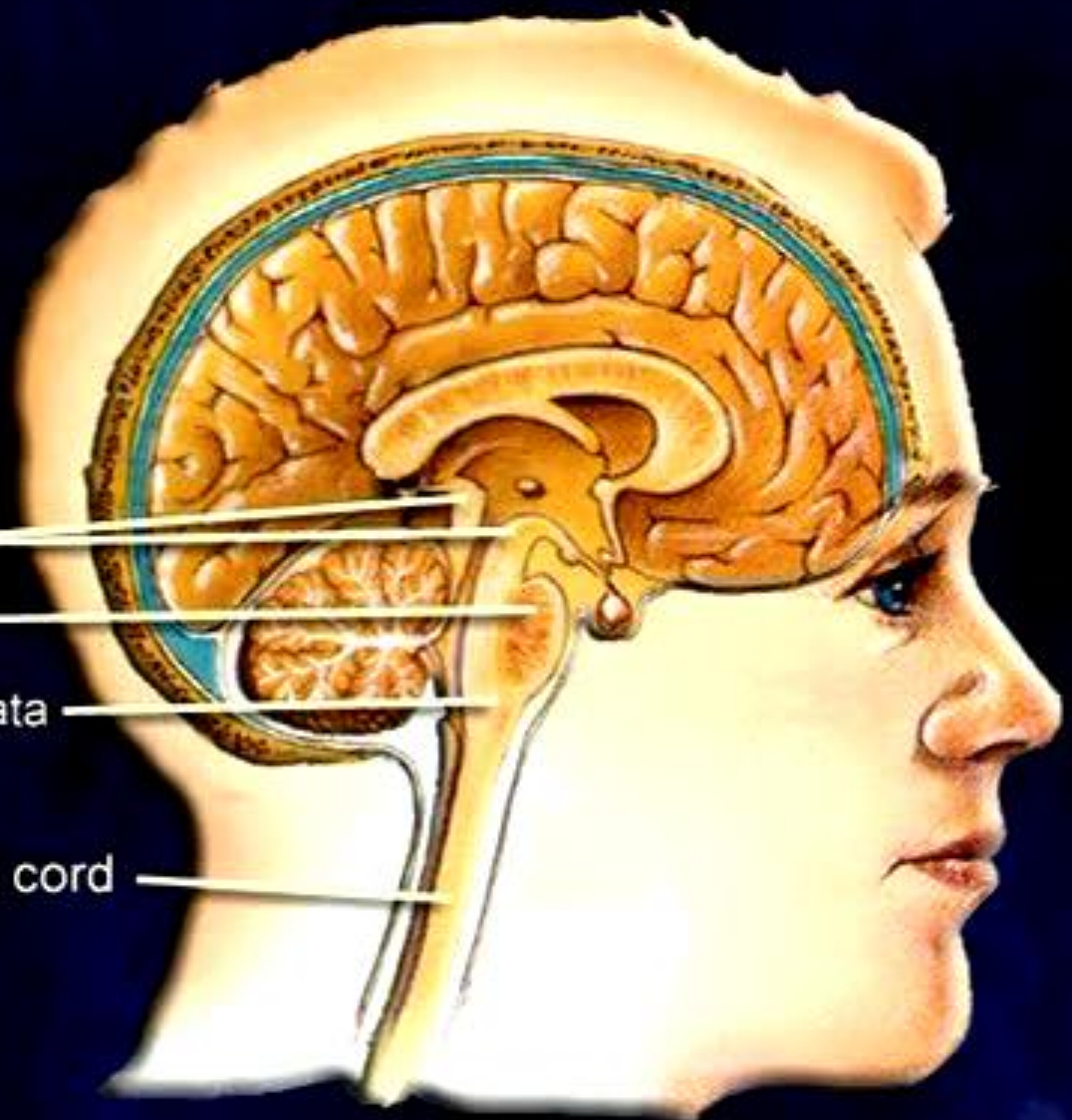
**BRAIN STEM**

Midbrain

Pons

Medulla oblongata

Spinal cord



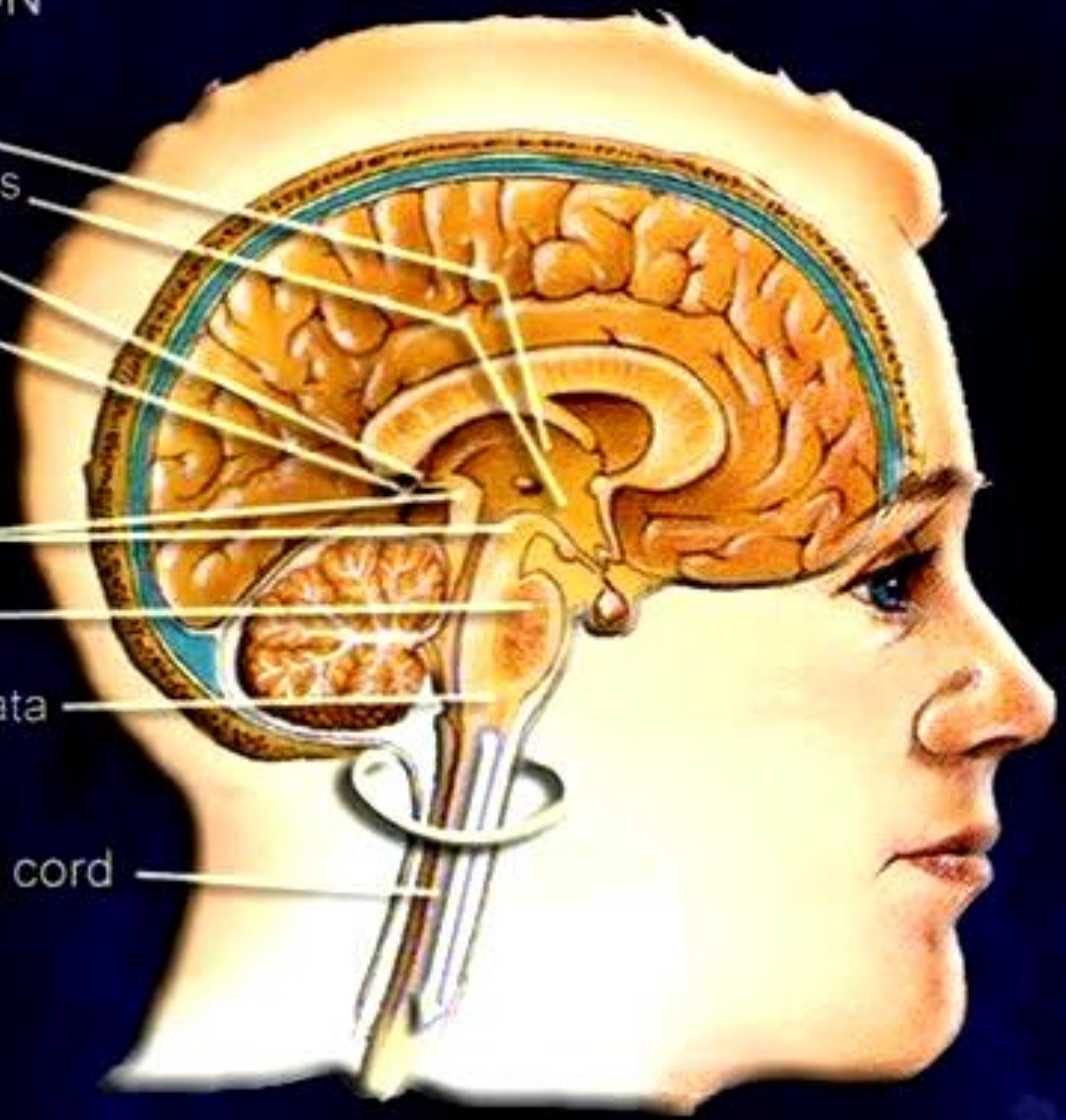
DIENCEPHALON

- Thalamus
- Hypothalamus
- Epithalamus
- Pineal gland

BRAIN STEM

- Midbrain
- Pons
- Medulla oblongata

Spinal cord



# Structure and Function

## Brainstem 뇌간

Made up of the midbrain; pons and the medulla oblongata

### Midbrain

- Involved with visual reflexes

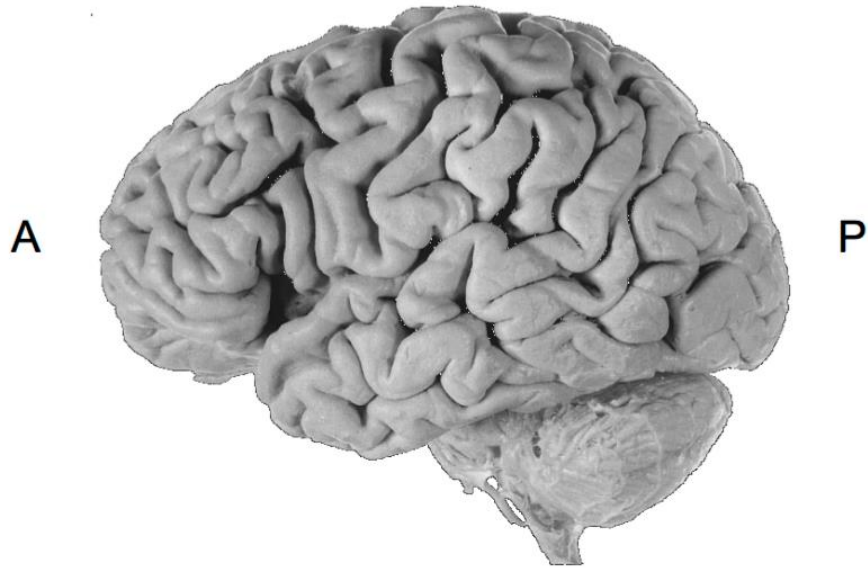### Pons

- Located between the midbrain and the medulla oblongata
- Controls certain respiratory functions

### Medulla Oblongata

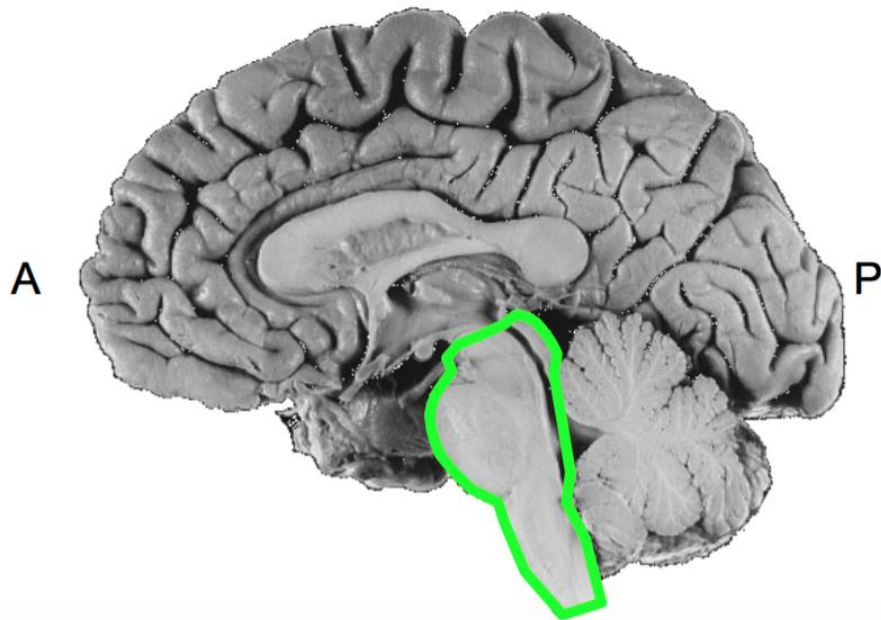
- Contains centers that regulate heart and lung functioning, swallowing, coughing, vomiting and sneezing

# Components of the Brain



## Brainstem

- Midbrain
- Pons
- Medulla



### 1. Conduit Functions

Ascending tracts to the thalamus or cerebellum

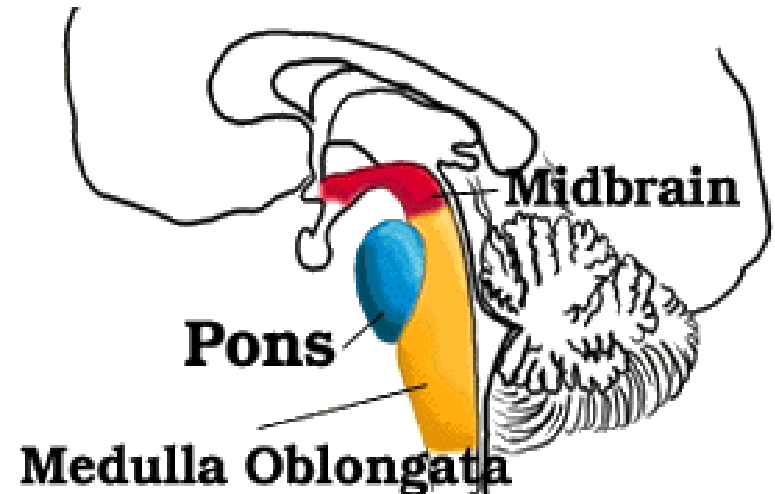
Descending tracts to the spinal cord

### 2. Cranial Nerve Functions

Contains an array of cranial nerve nuclei

# Brainstem

- The lower extension of the brain where it connects to the spinal cord.
- Neurological functions located in the brainstem include those necessary for survival (breathing, digestion, heart rate, blood pressure) and for arousal (being awake and alert).
- Most of the cranial nerves come from the brainstem.
- The brainstem is the pathway for all fiber tracts passing up and down from peripheral nerves and spinal cord to the highest parts of the brain.



- **Midbrain** - The midbrain serves as the nerve pathway of the cerebral hemispheres and contains auditory and visual reflex centers.
- **Pons** - The pons is a bridge-like structure which links different parts of the brain and serves as a relay station from the medulla to the higher cortical structures of the brain. It contains the respiratory center.
- **Medulla Oblongata** - The medulla oblongata functions primarily as a relay station for the crossing of motor tracts between the spinal cord and the brain. It also contains the respiratory, vasomotor and cardiac centers, as well as many mechanisms for controlling reflex activities such as coughing, gagging, swallowing and vomiting.

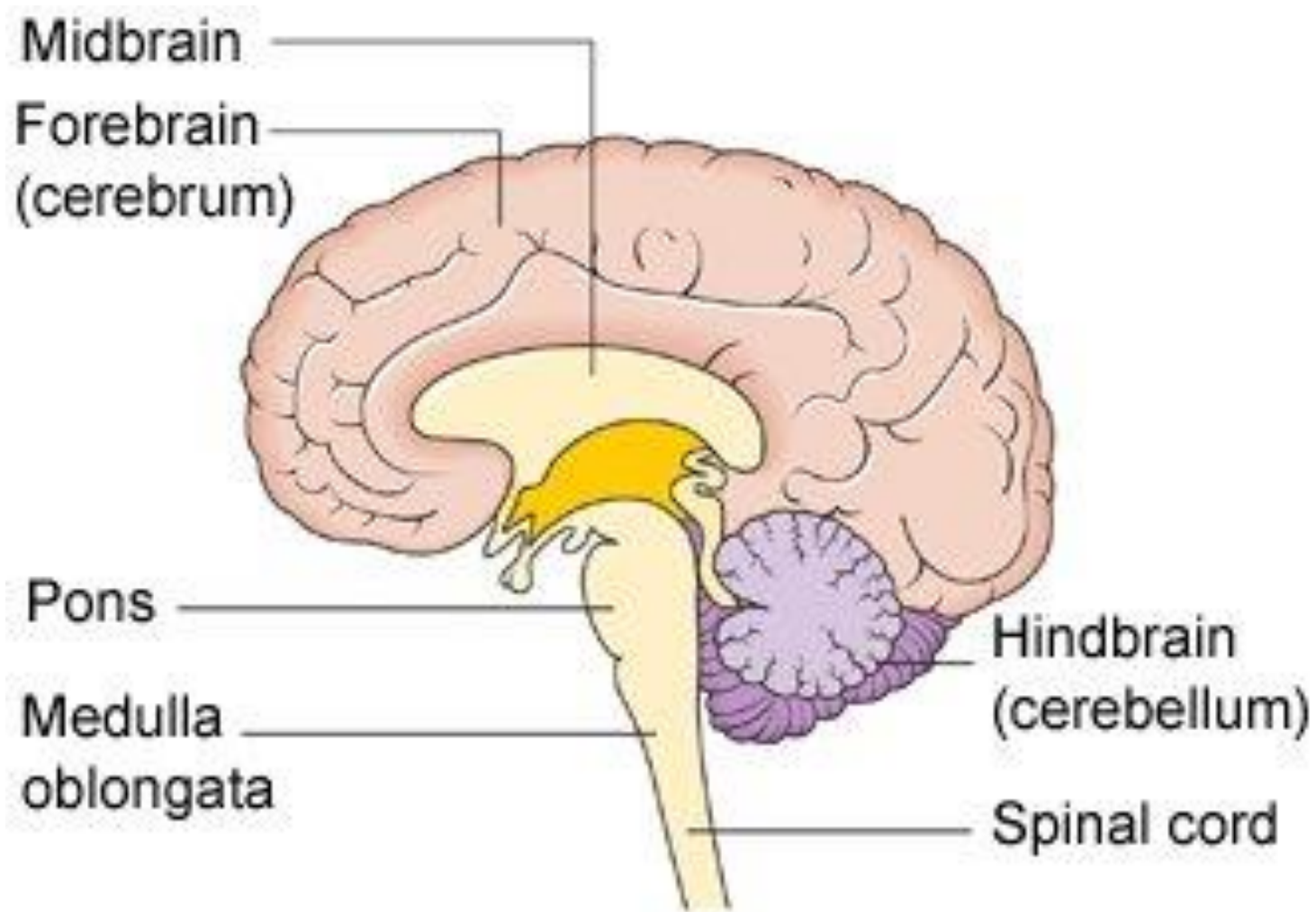


Diagram showing the brain stem which includes the medulla oblongata, the pons and the midbrain

뇌간 (brain stem) : 생명 유지 중추

간뇌 → 중뇌 → 뇌교(pons) → 연수(medulla oblongata) (숨뇌)

- 중뇌(mid brain) : 간뇌·뇌교·소뇌의 연결

중뇌개 – 상구 (시각전도·반사 중추)

하구 (청각전도·반사 중추)

- 교뇌(pons) : 호흡운동 조절

- 숨뇌(medulla oblongata) : 추체로 교차

생명중추 (호흡, 심장, 연하, 구토, 정신적 발한 중추)



# Structure and Function

## Cerebellum

**Area that coordinates musculoskeletal movement to maintain posture, balance, and muscle tone**



## Cerebellum (소뇌)

- The **cerebellum** (Latin for *little brain*) is a region of the brain that plays an important role in motor control.
- It may also be involved in some cognitive functions such as attention and language, and in regulating fear and pleasure responses.
- The cerebellum does not initiate movement, but it contributes to coordination, precision, and accurate timing.
- It receives input from sensory systems and from other parts of the brain and spinal cord, and integrates these inputs to fine tune motor activity.
- Because of this fine-tuning function, damage to the cerebellum does not cause paralysis, but instead produces disorders in fine movement, equilibrium, posture, and motor learning.

## Cerebellum(계속)

- 대뇌 후두엽과 분리, 중뇌·뇌교·연수(숨뇌)와 연결
- 약 120~130 g 추체외로계의 중추
- 많은 주름의 소뇌피질(회백질)과 수질(백질)
- 몸의 평형 유지, 수의적 운동 조절, 근육의 긴장

### - 구성

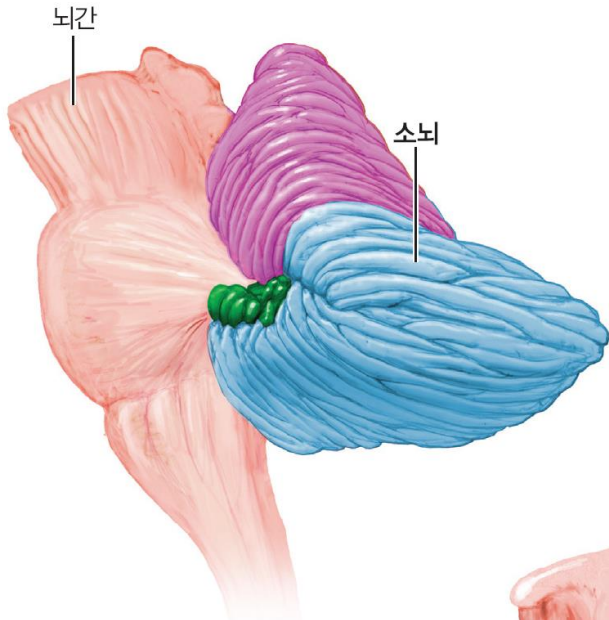
소뇌반구 (좌·우), 층부 (중앙)

수질: 백질, 소뇌핵, 소뇌활수(**arbor vitae**)

소뇌핵 (**cerebellar nucleus**)

## 5.8 소뇌(cerebellum)

- 균형을 잡고, 의지적 동작을 계획하고 실행하는 데 중요
- 3 기능적 부위들(**그림**)
  - **전정소뇌(vestibulocerebellum)**
    - 몸의 균형유지와 안구 움직임의 조절
  - **척수소뇌(spinoocerebellum)**
    - 근육 긴장도를 증가시키며, 숙련된 의지적 운동을 조정
  - **대뇌소뇌(cerebrocerebellum)**
    - 피질의 운동영역에 입력을 보내어 의지적 운동을 계획하고 시작하게 함
    - 절차기억을 저장



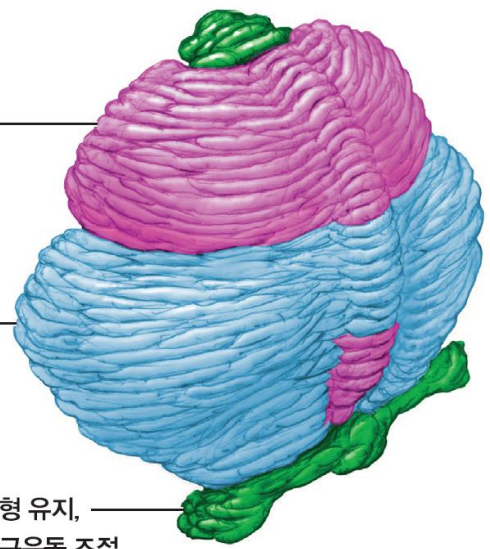
(a) 소뇌의 전체적인 모습



근육의 긴장도 조절,  
숙련된 수의적  
운동의 조정

의지적 활동을  
계획하고 시작함,  
절차기억의 저장

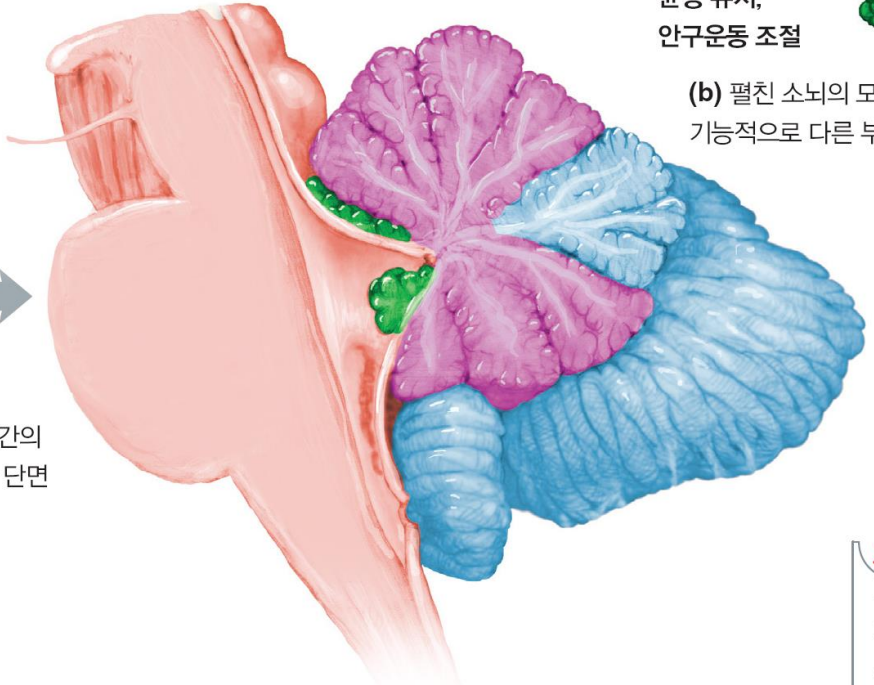
균형 유지,  
안구운동 조절



(b) 펼친 소뇌의 모습은 세 가지  
기능적으로 다른 부위들을 보여준다.



소뇌와 뇌간의  
중앙 시상 단면



(c) 소뇌의 내부 구조

**보기**

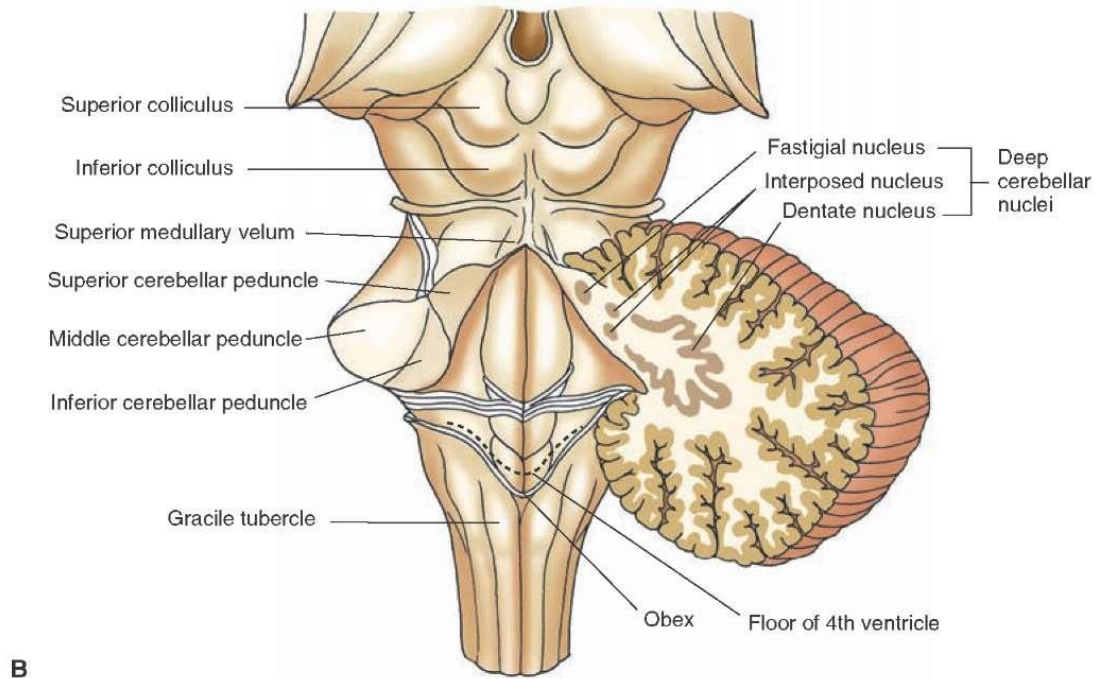
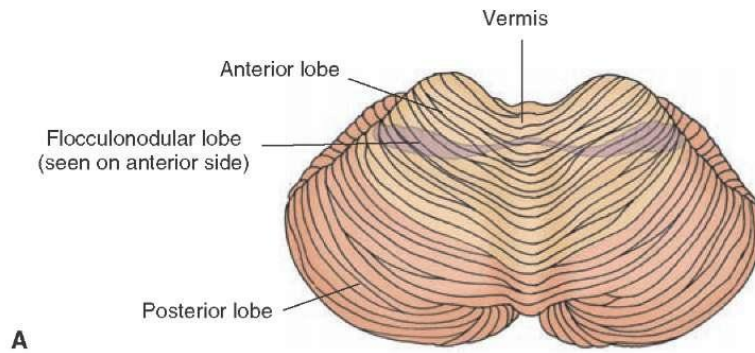
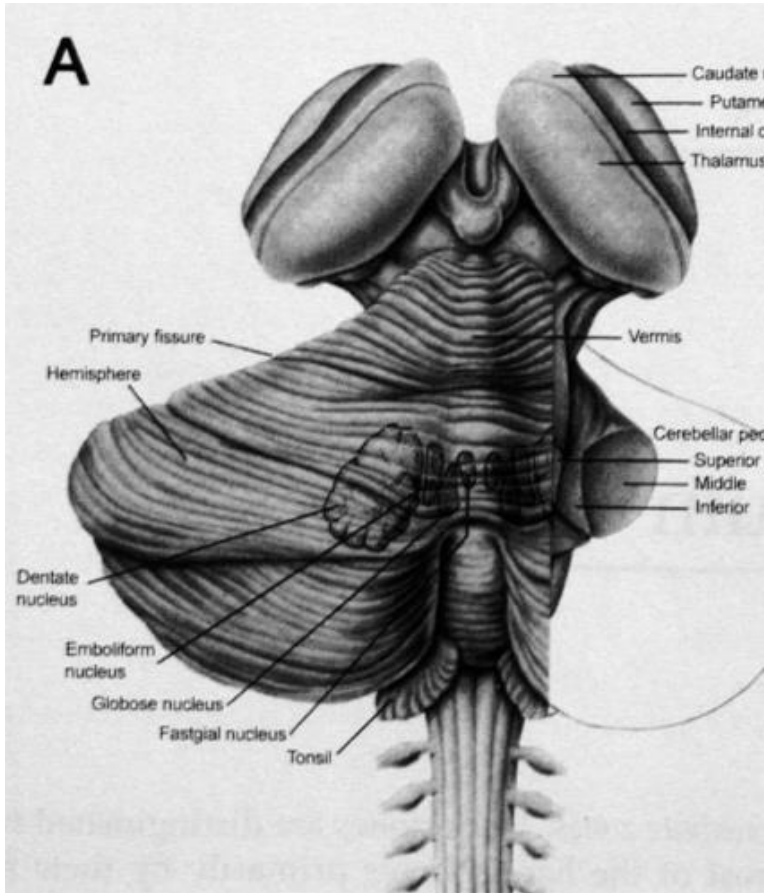
- 전정소뇌
- 척수소뇌
- 대뇌소뇌

## 소뇌핵 (cerebellar nucleus)

- 치상핵 (dentate nucleus): 대뇌 의지운동 억제와 섬세한 손 운동
- 전상핵 (emboliform nucleus): 서 있는 자세에서 중력 지탱
- 구상핵 (globose nucleus): 골격근의 고유감각
- 실정핵 (fastigial nucleus): 공간에서의 평형감각 조절

## 소뇌의 기능 부전

- 협동운동 불능, 진전 (tremor), 길항운동 반복 불능증, 소뇌성 안구 진탕, 현훈 (현기증, vertigo), 언어장애



# Structure and Function

## Cerebrum

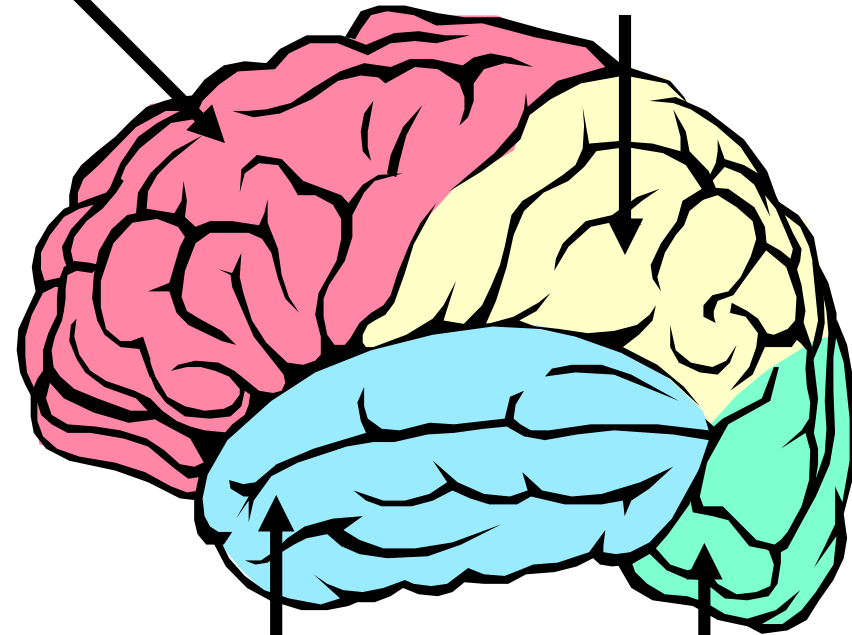
- Located above the cerebellum
- Contains two hemispheres with an outer portion called the **cerebral cortex**
- The two hemispheres are connected by a bridge of nerve fibers that relay information between the two hemispheres called the **corpus callosum**
- The left and right lobes are each divided into four lobes or parts:

- parietal lobe
- frontal lobe
- temporal lobe
- occipital lobe

두정엽  
전두엽  
측두엽  
후두엽

Frontal

Parietal



Temporal

Occipital



# Cerebrum

## 1. cerebral cortex

- A sheet of neural tissue that is outermost to the cerebrum of the mammalian brain.
- It plays a key role in memory, attention, perceptual awareness, thought, language, and consciousness.
- It is constituted of up to six horizontal layers, each of which has a different composition in terms of neurons and connectivity.
- The human cerebral cortex is 2–4 mm (0.08–0.16 inches) thick.

# 대뇌 (Cerebrum)

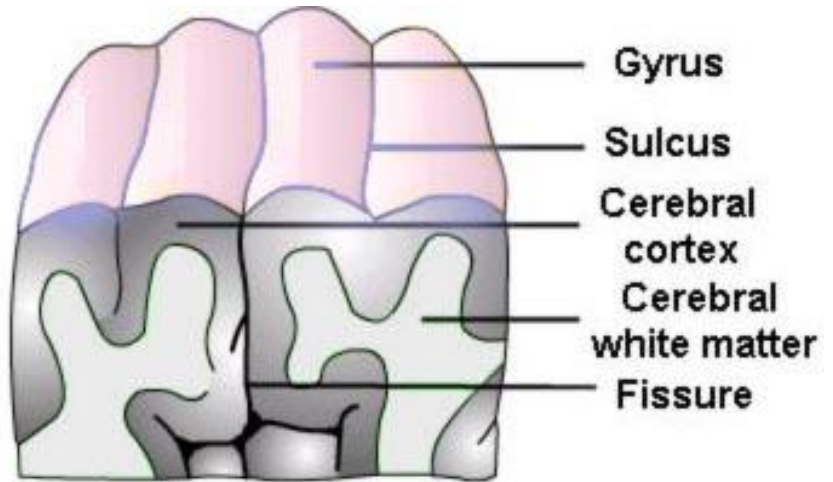
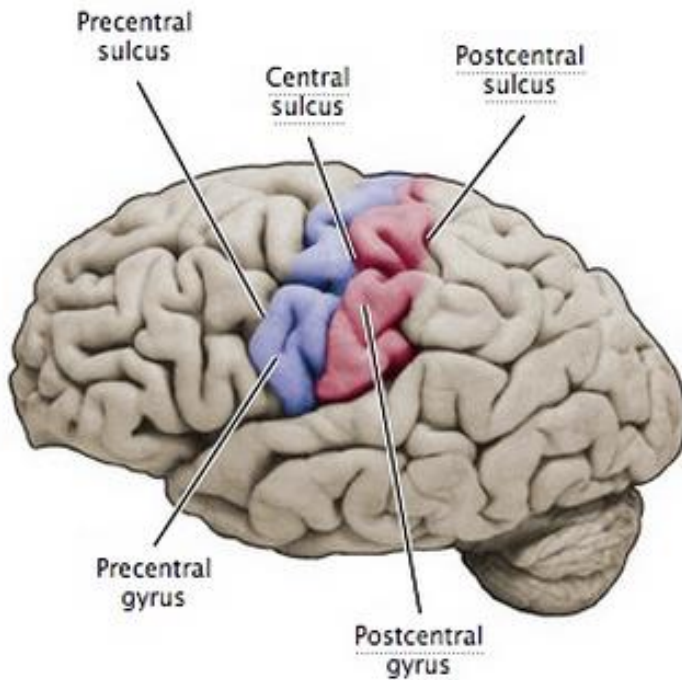
뇌의 가장 큰 부분 (80%), 가장 발달  
대뇌피질, 대뇌수질, 기저핵, 측내실로 구성

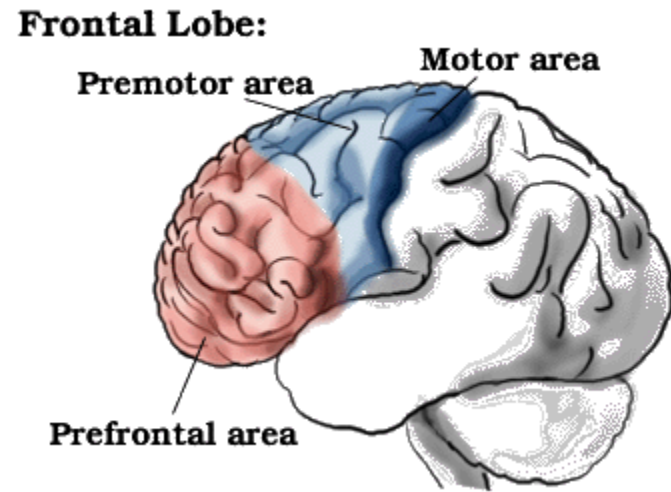
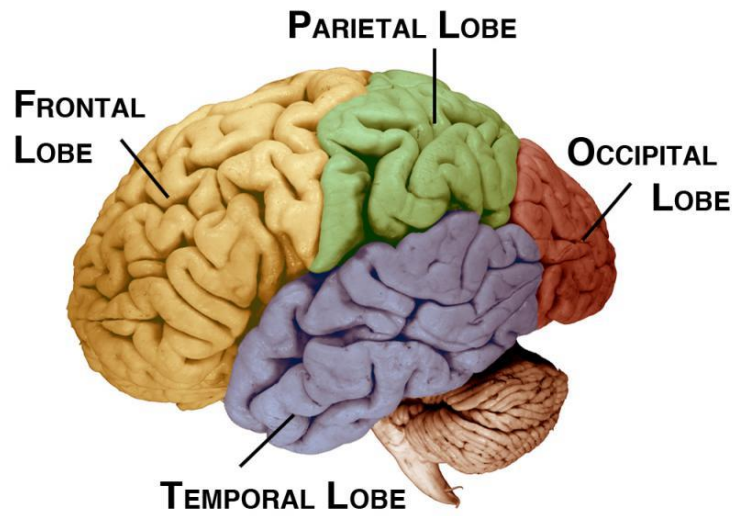
## 1. 대뇌피질: (cerebral cortex)

- 회백질, 6층의 신경세포가 배열, 2.5-3 mm 두께
- gray matter: cell body, dendrites 로 구성
- 표면에 많은 주름
- 약 140-170억 개의 신경세포로 구성  
: 10억개 뉴런, 1조의 시냅스
- 좌, 우 대뇌 반구로 구성, 내측면은 뇌량(corpus callosum)  
으로 연결
- 대뇌엽 : 전두엽(이마엽), 두정엽(마루엽),  
측두엽 (관자엽), 후두엽 (뒤통수엽)

# 기능

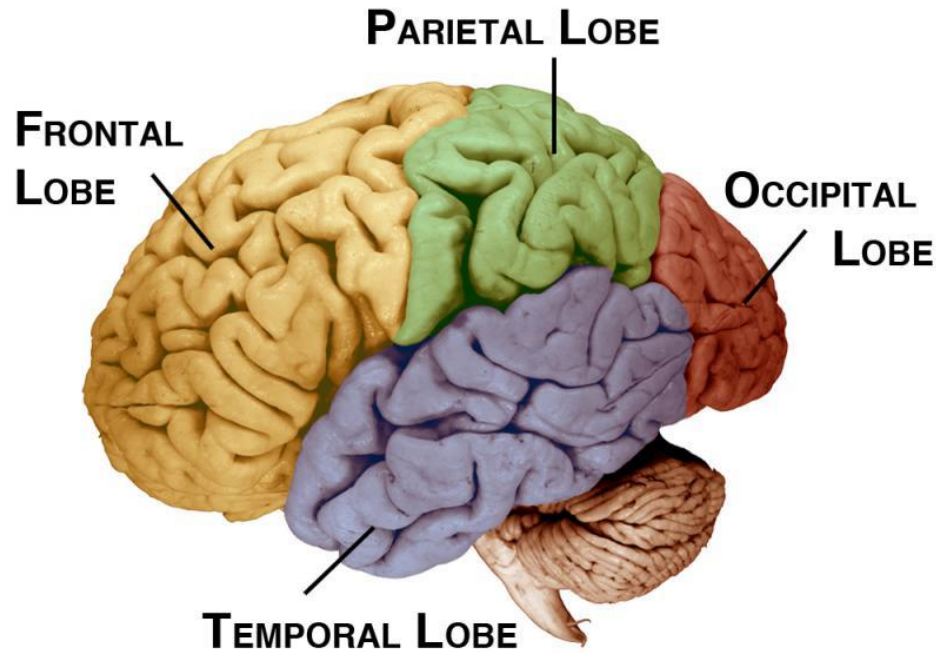
- 지성의 중추로 대부분기능 수행, 부분마다 특징적
- 운동 중추 (중심전회) cf. 뇌회: (뇌이랑, gyri)
- 감각중추 (중심후구) cf. 뇌구 (뇌고랑, sulci)
- 청각중추 (측두엽), 시각중추 (후두엽),
- 미각중추 (두정엽 중심후회 저면)





**Frontal Lobe** - Front part of the brain; involved in planning, organizing, problem solving, selective attention, personality and a variety of "higher cognitive functions" including behavior and emotions.

- The anterior (front) portion: higher cognitive functions & personality.
- The posterior (back) portion : motor areas
- The frontal lobe is divided from the parietal lobe by the central sulcus.

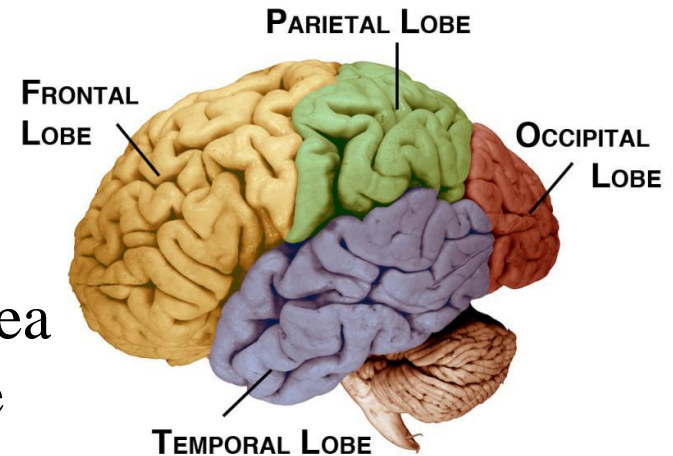


## **Occipital Lobe –**

- Region in the back of the brain which processes visual information.
- Not only is the occipital lobe mainly responsible for visual reception, it also contains association areas that help in the visual recognition of shapes and colors.
- Damage to this lobe can cause visual deficits.

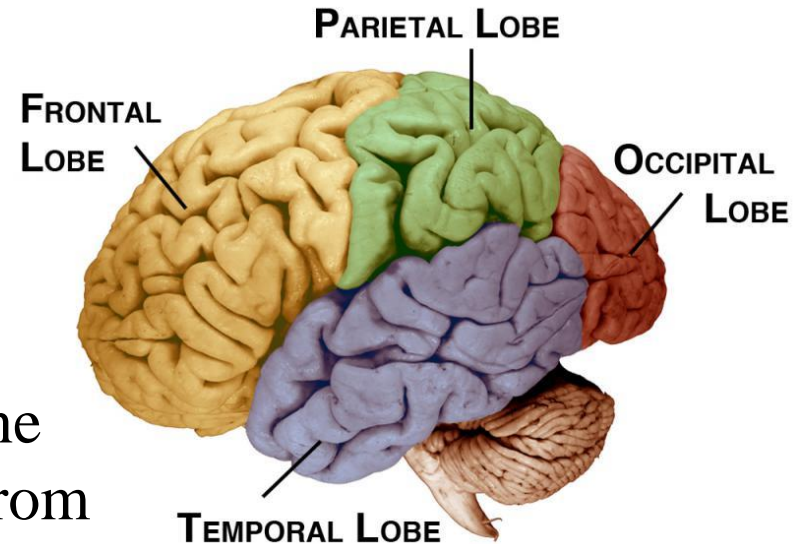
**Parietal Lobe** - One of the two parietal lobes of the brain located behind the frontal lobe at the top of the brain.

- Parietal Lobe, Right - Damage to this area can cause **visuo-spatial deficits** (e.g., the patient may have difficulty finding their way around new, or even familiar, places).
- Parietal Lobe, Left - Damage to this area may disrupt a patient's ability to **understand spoken and/or written language**.
- The parietal lobes contain the **primary sensory cortex** which controls sensation (touch, pressure).
- Behind the primary sensory cortex is a large association area that controls **fine sensation** (judgment of texture, weight, size, shape).



**Temporal Lobe** - There are two temporal lobes, one on each side of the brain located at about the level of the ears.

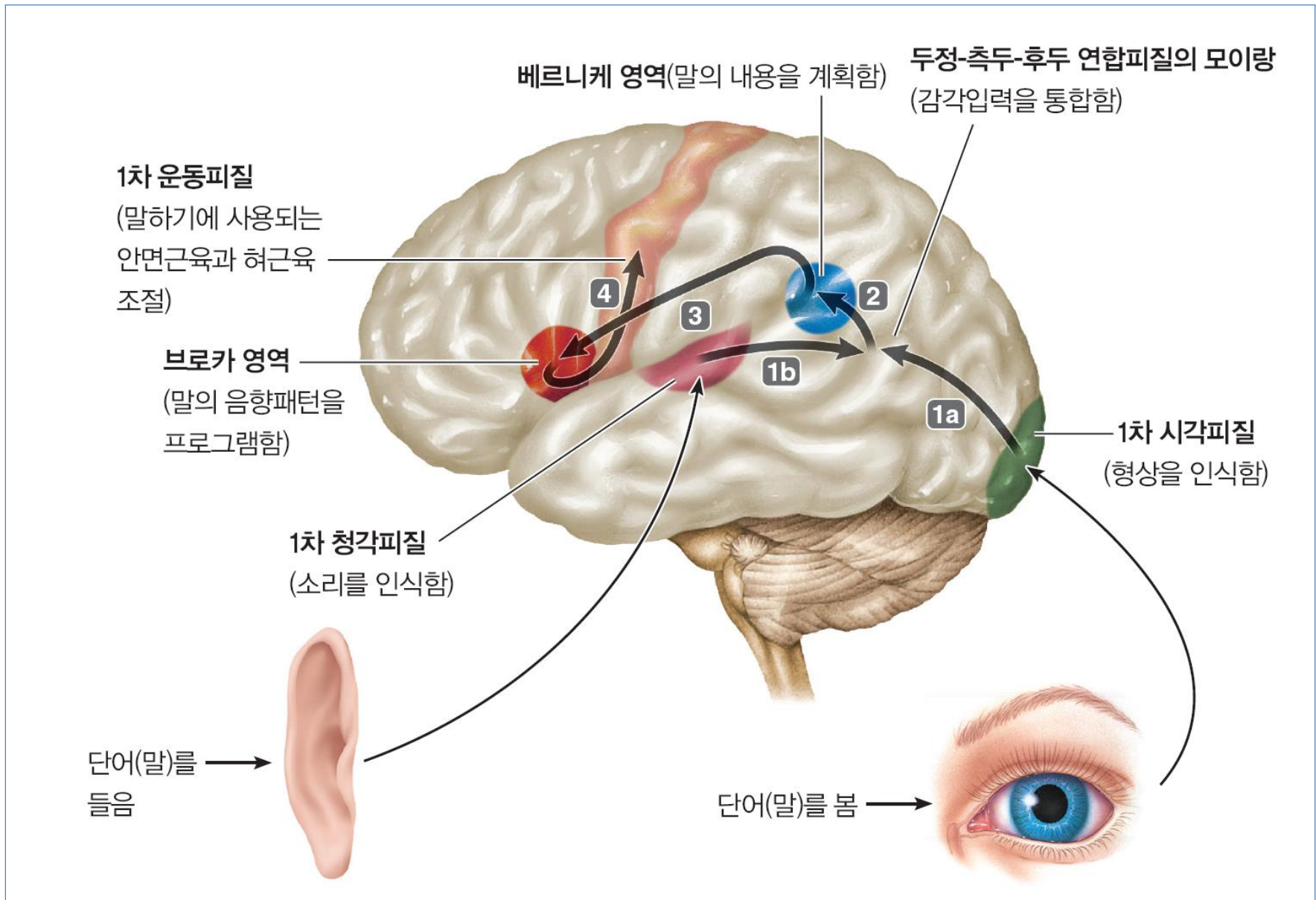
- These lobes allow a person to tell one smell from another and one sound from another.
- They also help in sorting new information and are believed to be responsible for short-term memory.
- Right Lobe - Mainly involved in visual memory (i.e., memory for pictures and faces).
- Left Lobe - Mainly involved in verbal memory (i.e., memory for words and names).



# 언어(language)

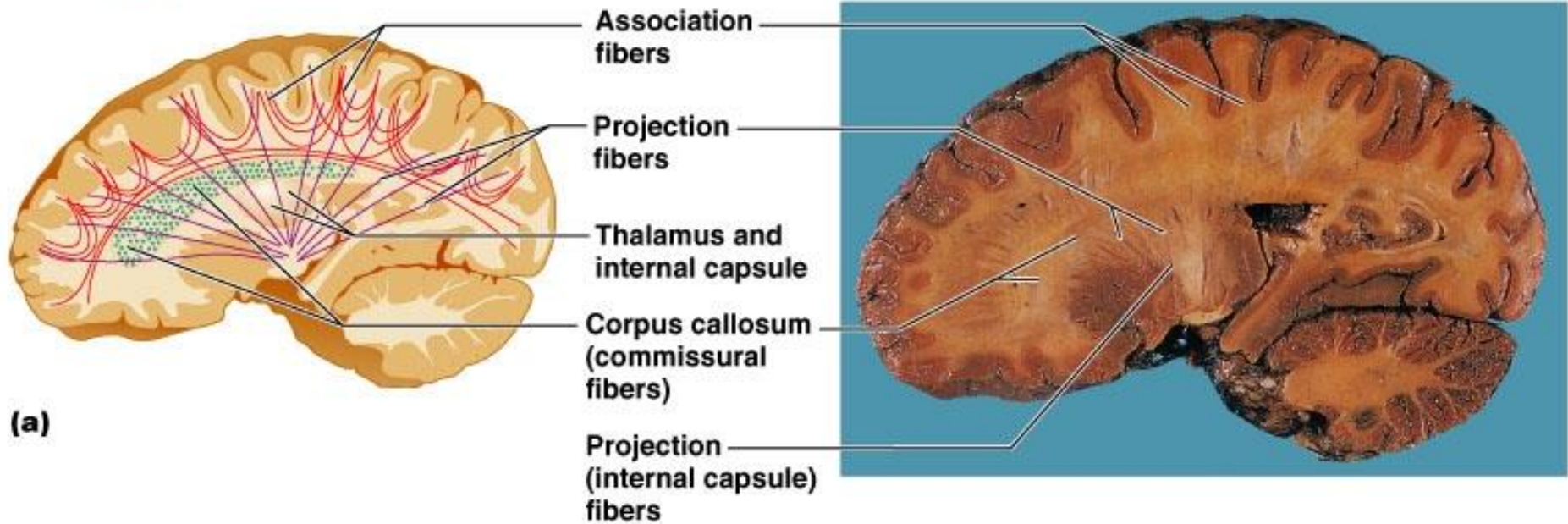
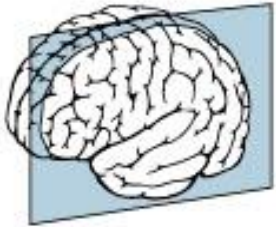
- 언어 기능에 특화 된 주요 피질 영역(**그림**)
  - 브로카 영역(Broca's area)
    - 말하기 능력 담당
  - 베르니케 영역(Wernicke's area)
    - 언어의 이해를 담당
    - 말이나 글로 표시되는 의미를 이해
    - 소리 있는 발성 패턴 형성
- 언어장애들: 실어증(aphasias), 발성장애, 읽기장애(dyslexia)



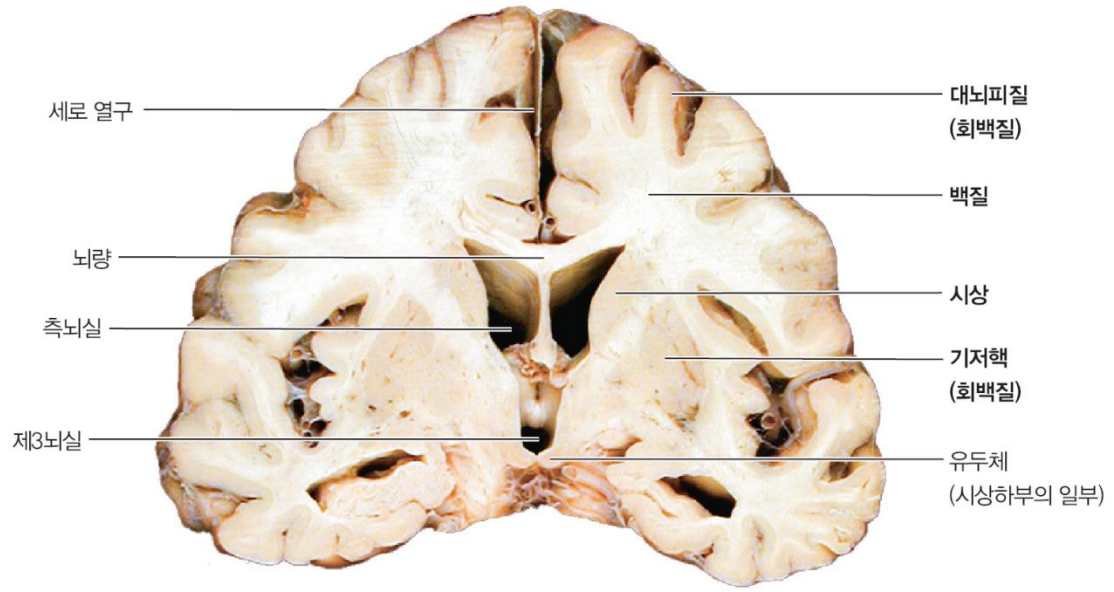
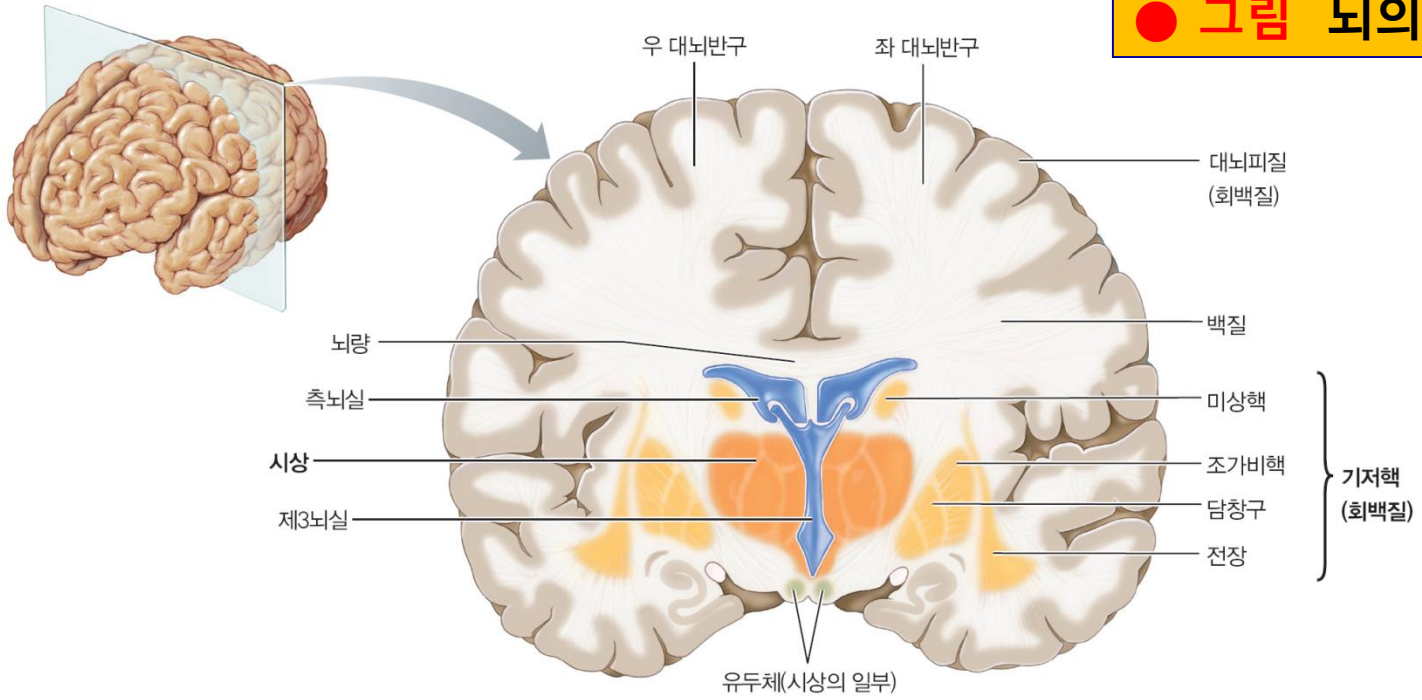


● 그림 보거나 들은 단어를 말할 때 사용되는 대뇌피질 경로.

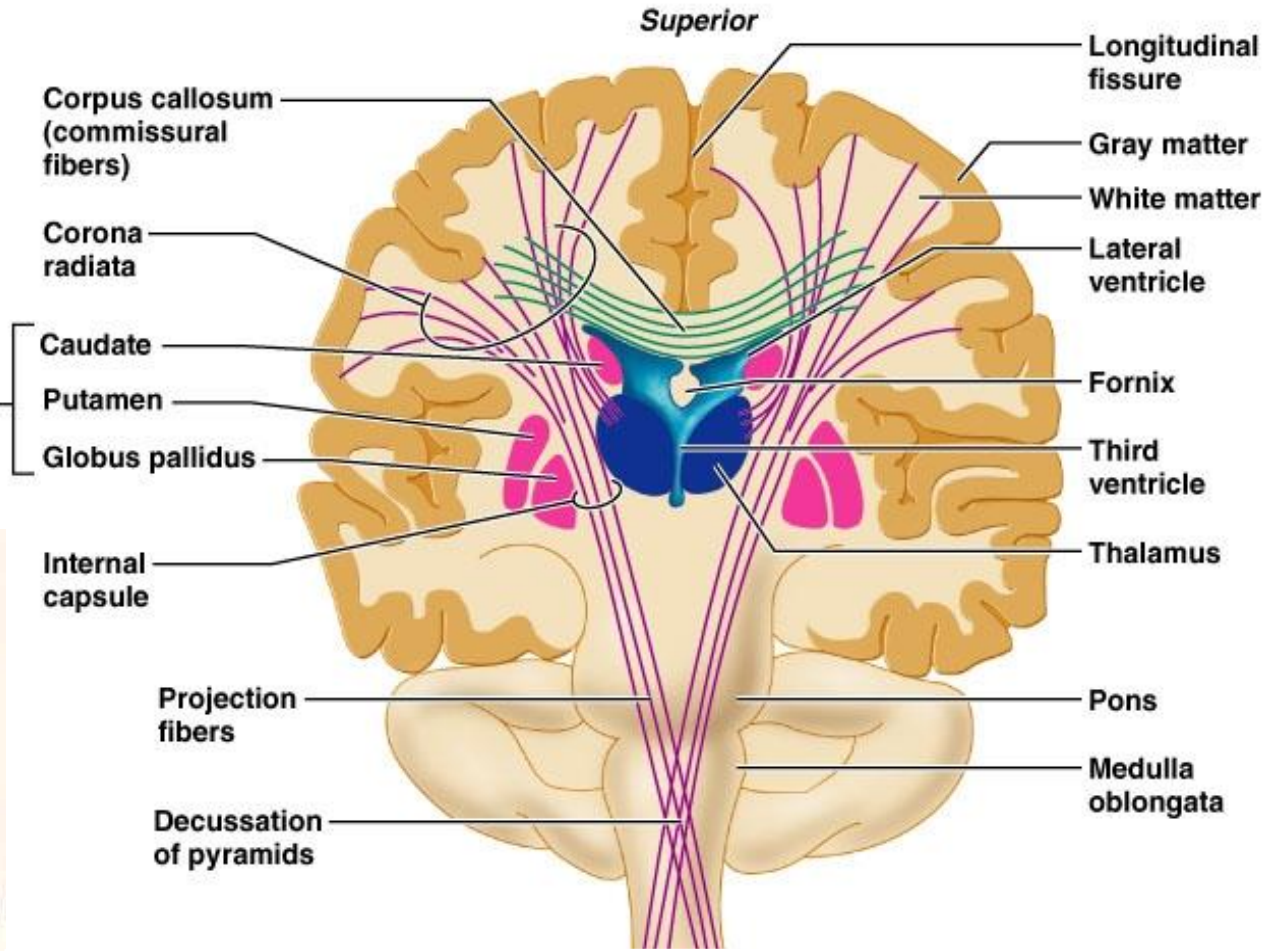
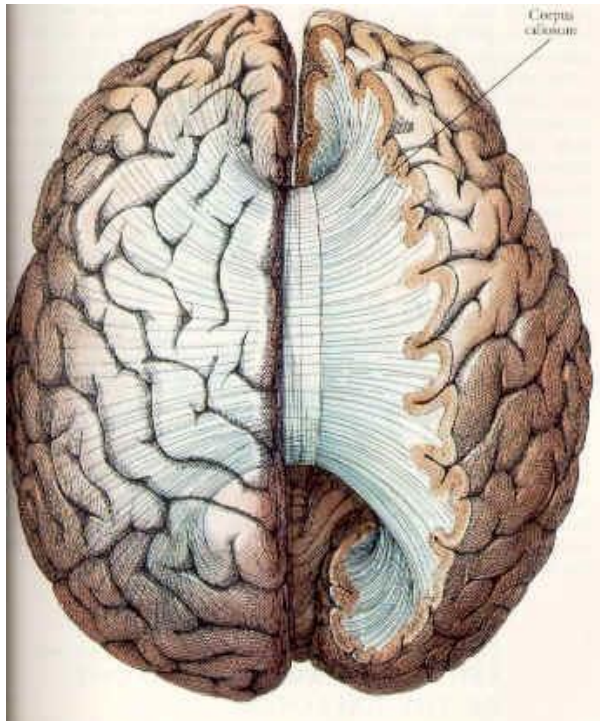
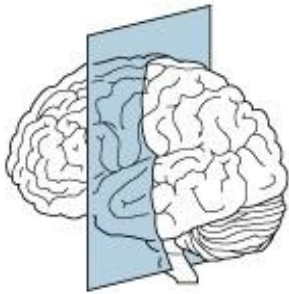
## 2. 대뇌수질 ( White Matter in the Brain)



**● 그림 뇌의 앞 단면**

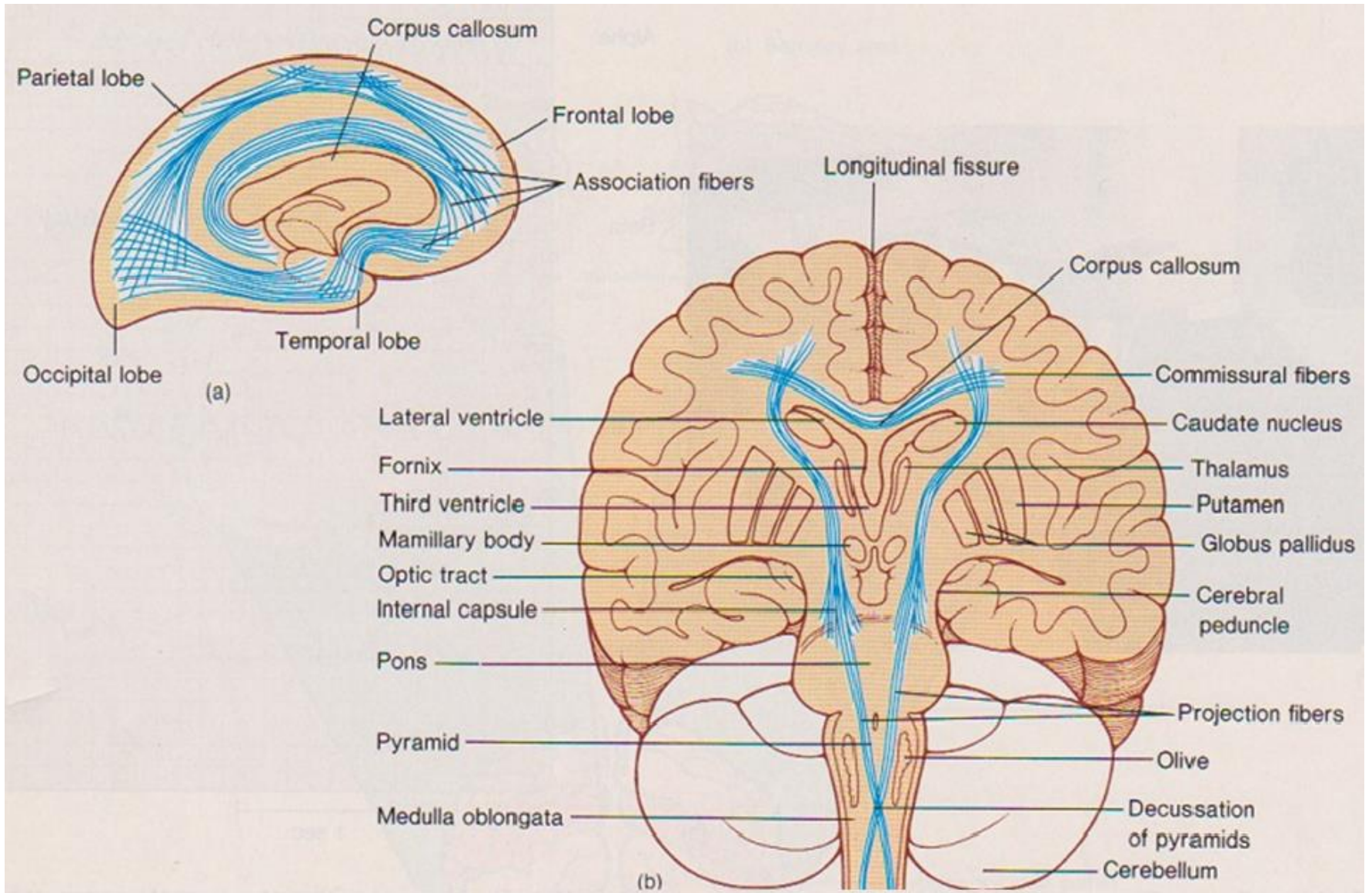


- 백질, 신경섬유 다발 (뇌의 각 부분 연결)
- Axon (축삭)으로 구성 → 말이집 형성
  - 백색을 띠는 이유는 지방함량이 높은 말이집 때문.
- 투사섬유 (projection fiber)
  - 대뇌피질(대뇌의 운동영역 )에서 척수로 신경흥분을 내려 보내는 섬유 연결, 방사관 형성
- 연합섬유 (association fiber)
  - 같은 쪽 대뇌 반구의 피질 사이를 연결
- 교련섬유 (commissural fiber)
  - 좌우 대뇌 반구의 피질세포를 연결, 뇌량



**Corpus callosum (commissural fibers)**

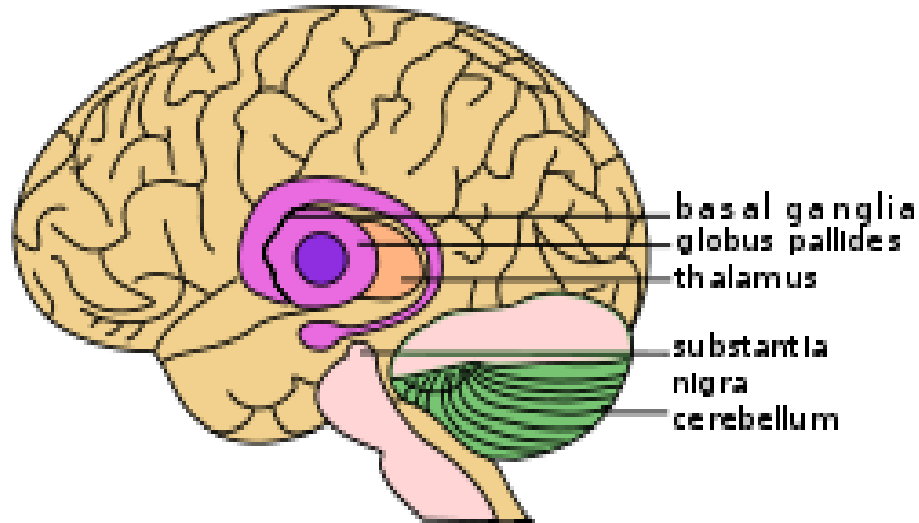
# White Matter in the Brain



### 3. 기저핵 (basal ganglia)

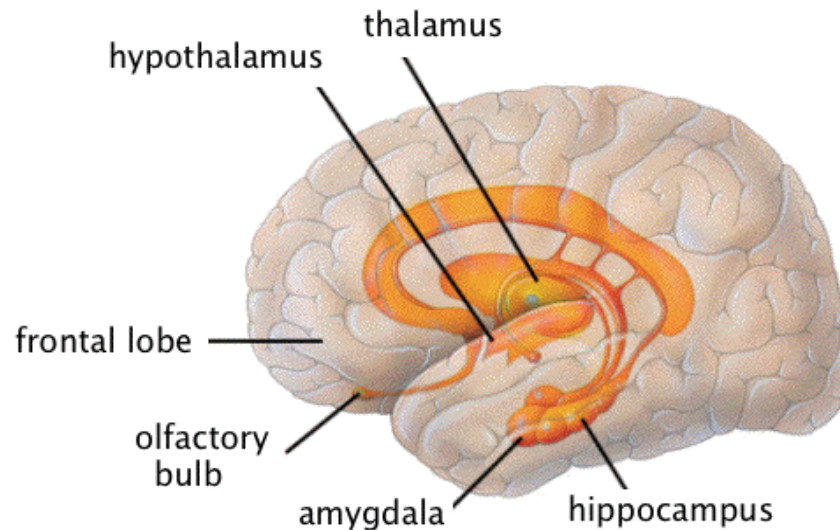
- 회백질이 대뇌 바닥 중심부에 묻혀 있는 것
- 내낭에 의해 내측군과 외측군으로 구분  
cf. 내낭 : 기저핵에 쌓인 신경섬유 통행로, 뇌출혈 빈발부위
- 전신 운동 기능 조정

Basal Ganglia and Related Structures of the Brain



## 4. Limbic system

- The limbic system is a complex set of structures that lies on both sides of the thalamus, just under the cerebrum.
- It includes the **hypothalamus**, the **hippocampus**, the **amygdala**, and several other nearby areas.
- It appears to be primarily responsible for our emotional life, and has a lot to do with the formation of memories.







# Structure and Function

## **Diencephalon** 사이뇌

**The deep portion of the brain containing:**

- thalamus**
- hypothalamus**
- epithalamus**
- ventral thalamus**

## **Functions**

- Serves as relay center for sensations**
- Integrates with the ANS in the control of:**

**Heart rate**

**Blood pressure**

**Temperature control**

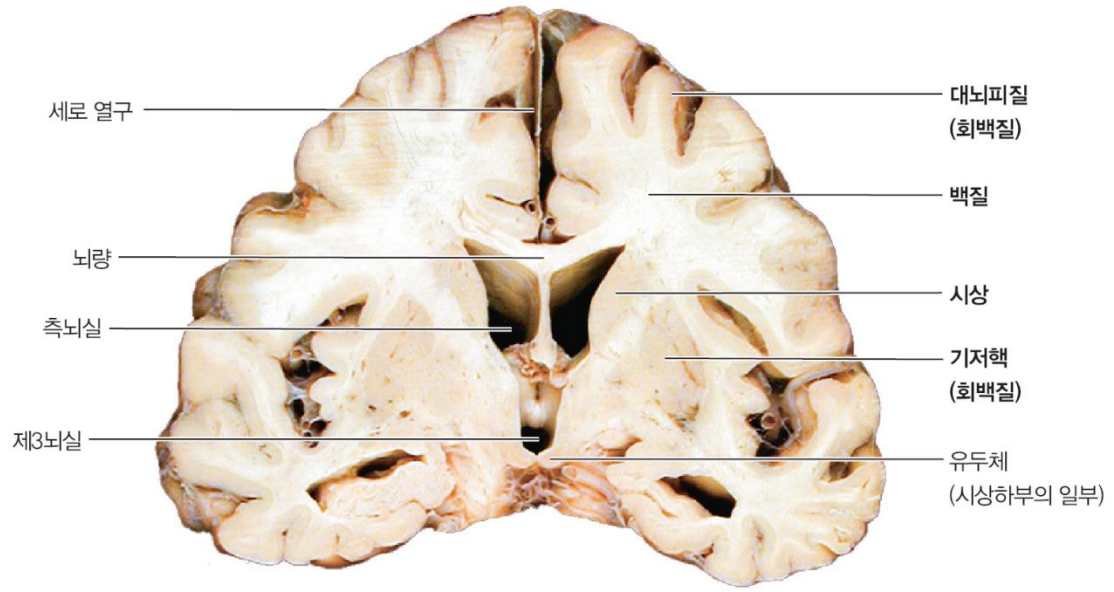
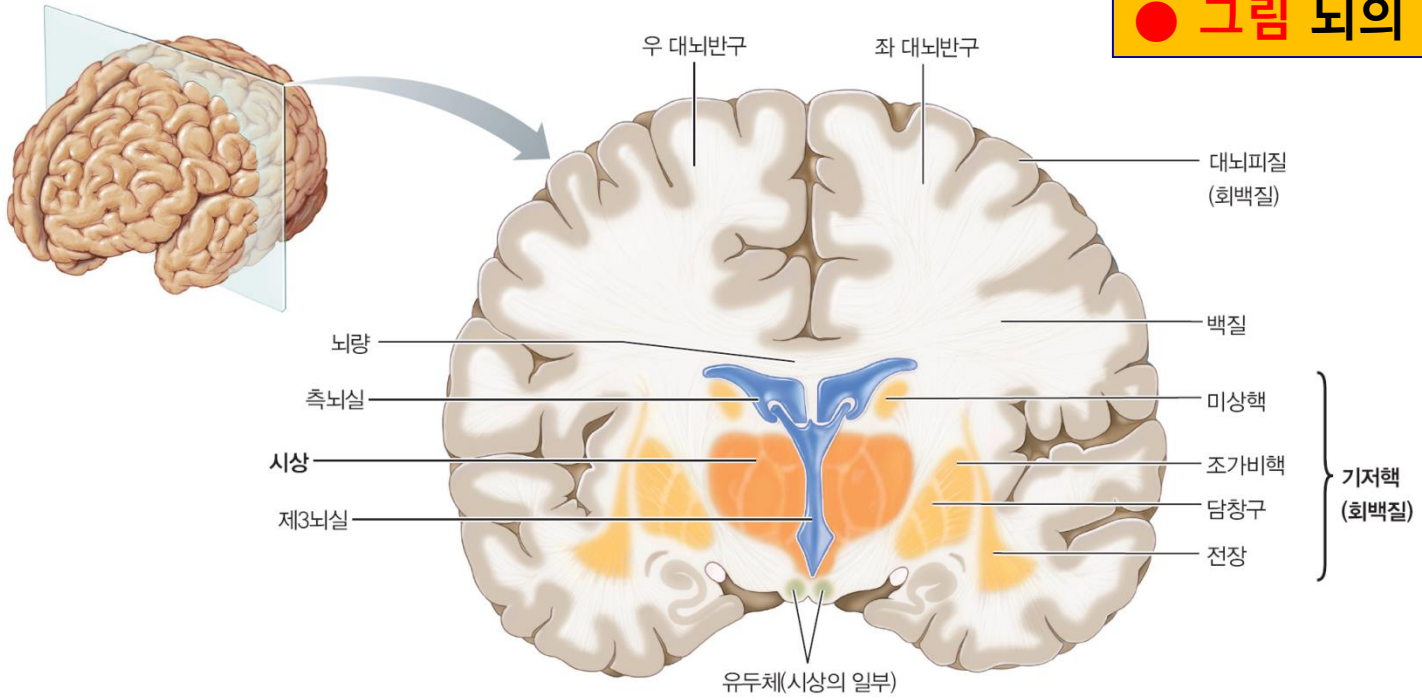
**Behavioral responses**

**Digestive functions**

**Water and electrolyte balance**

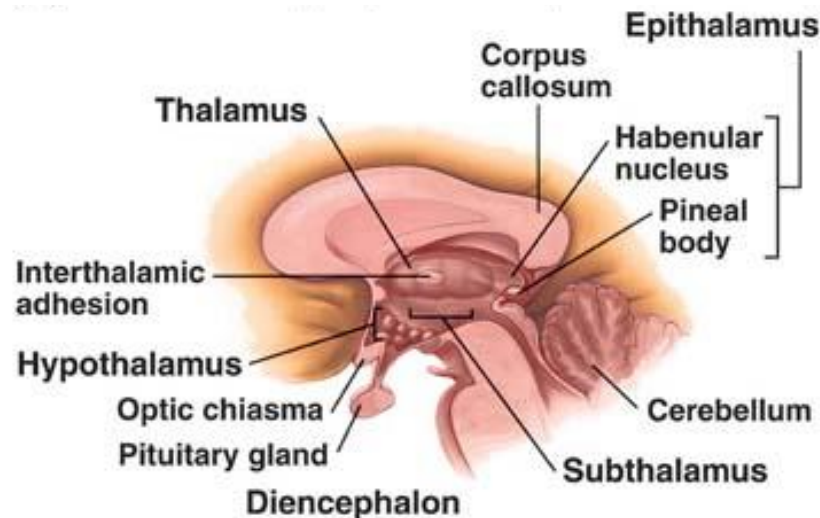
**Glandular activities**

● 그림 뇌의 앞 단면



# Diencephalon

- The **diencephalon** ("interbrain") is the region of the vertebrate **neural tube** which gives rise to posterior forebrain structures.
- In adults, the Diencephalon appears at the upper end of the brain stem, situated between the cerebrum and the brain stem.
- It is made up of four distinct components: the **thalamus**, the **subthalamus**, the **hypothalamus** and the **epithalamus**.



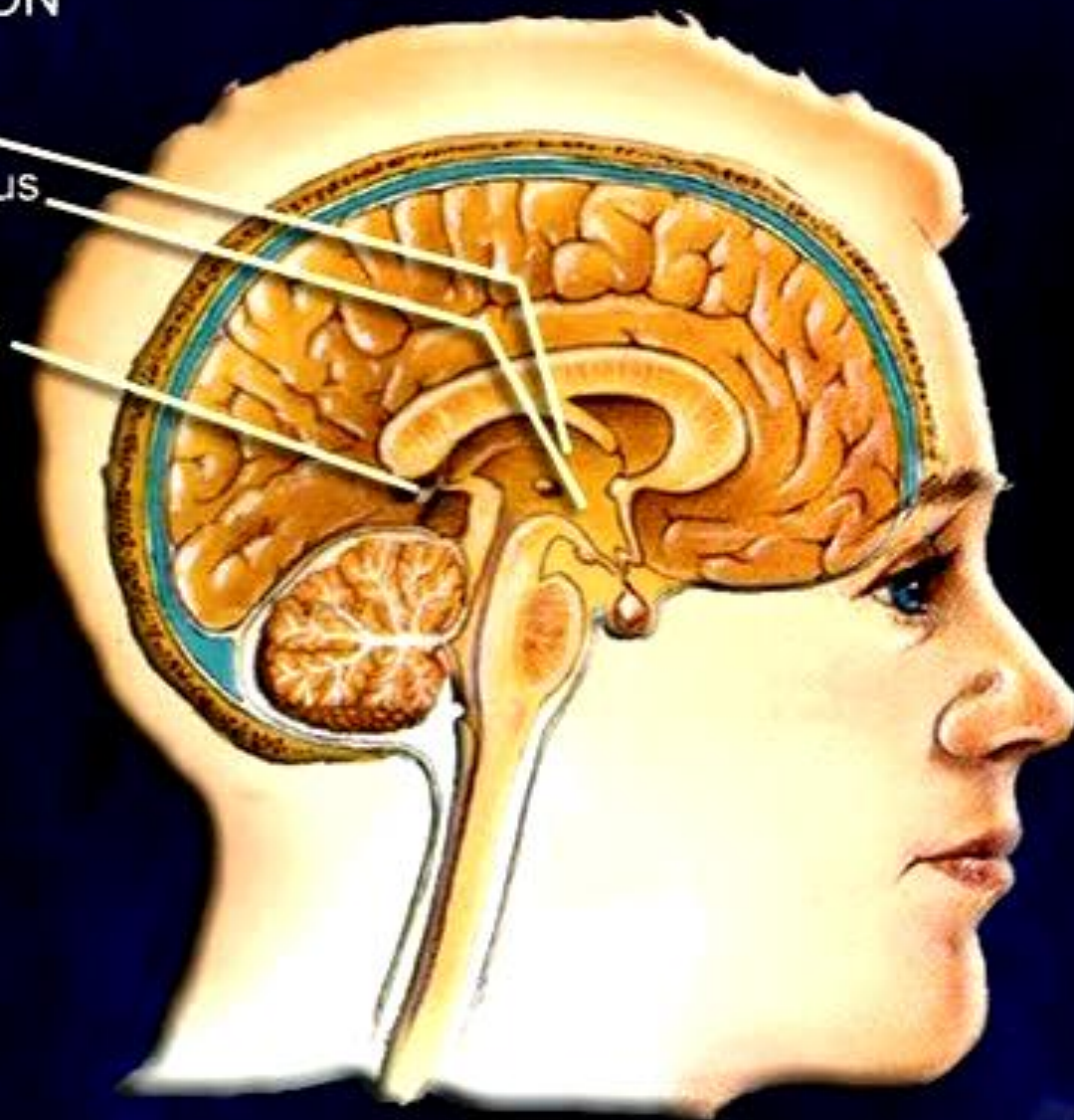
# DIENCEPHALON



Thalamus

Hypothalamus

Pineal gland



# Thalamus

- The **thalamus** (from Greek *θάλαμος* = *room, chamber*) is a midline paired symmetrical structure within the brains of vertebrates, including humans.
- It is situated between the cerebral cortex and midbrain, both in terms of location and neurological connections.
- Its function includes relaying sensation, spatial sense, and motor signals to the cerebral cortex, along with the regulation of consciousness, sleep, and alertness.

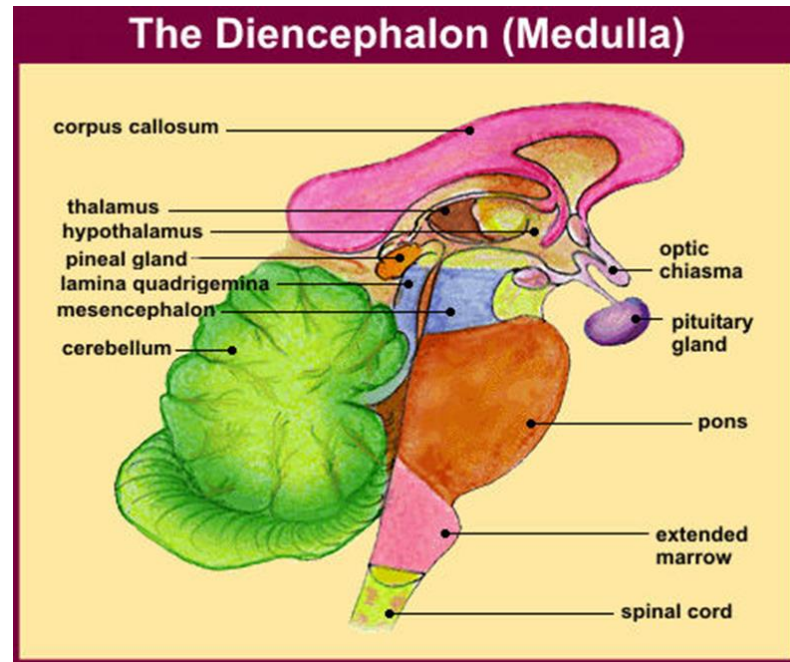
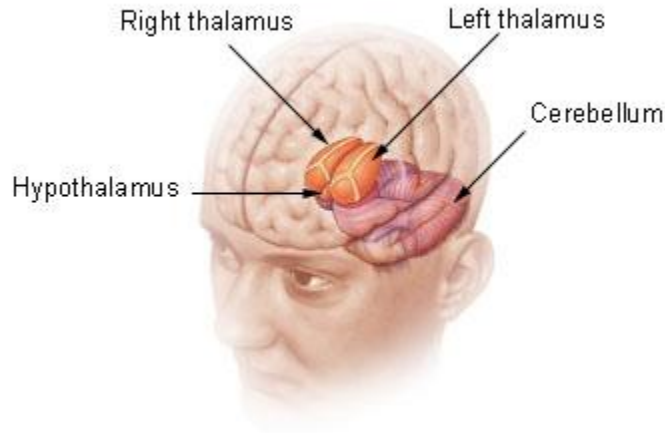
# Hypothalamus

- The **hypothalamus** (from Greek ὑπό = *under* and θάλαμος = *room, chamber*) is a portion of the brain that contains a number of small nuclei with a variety of functions.
- One of the most important functions of the hypothalamus is to link the nervous system to the endocrine system via the pituitary gland (hypophysis)(뇌하수체).
- The hypothalamus is responsible for certain metabolic processes and other activities of the autonomic nervous system.
- It synthesizes and secretes certain neurohormones, often called hypothalamic-releasing hormones, and these in turn stimulate or inhibit the secretion of pituitary hormones.
- The hypothalamus controls body temperature, hunger, thirst, fatigue, sleep, and circadian cycles.

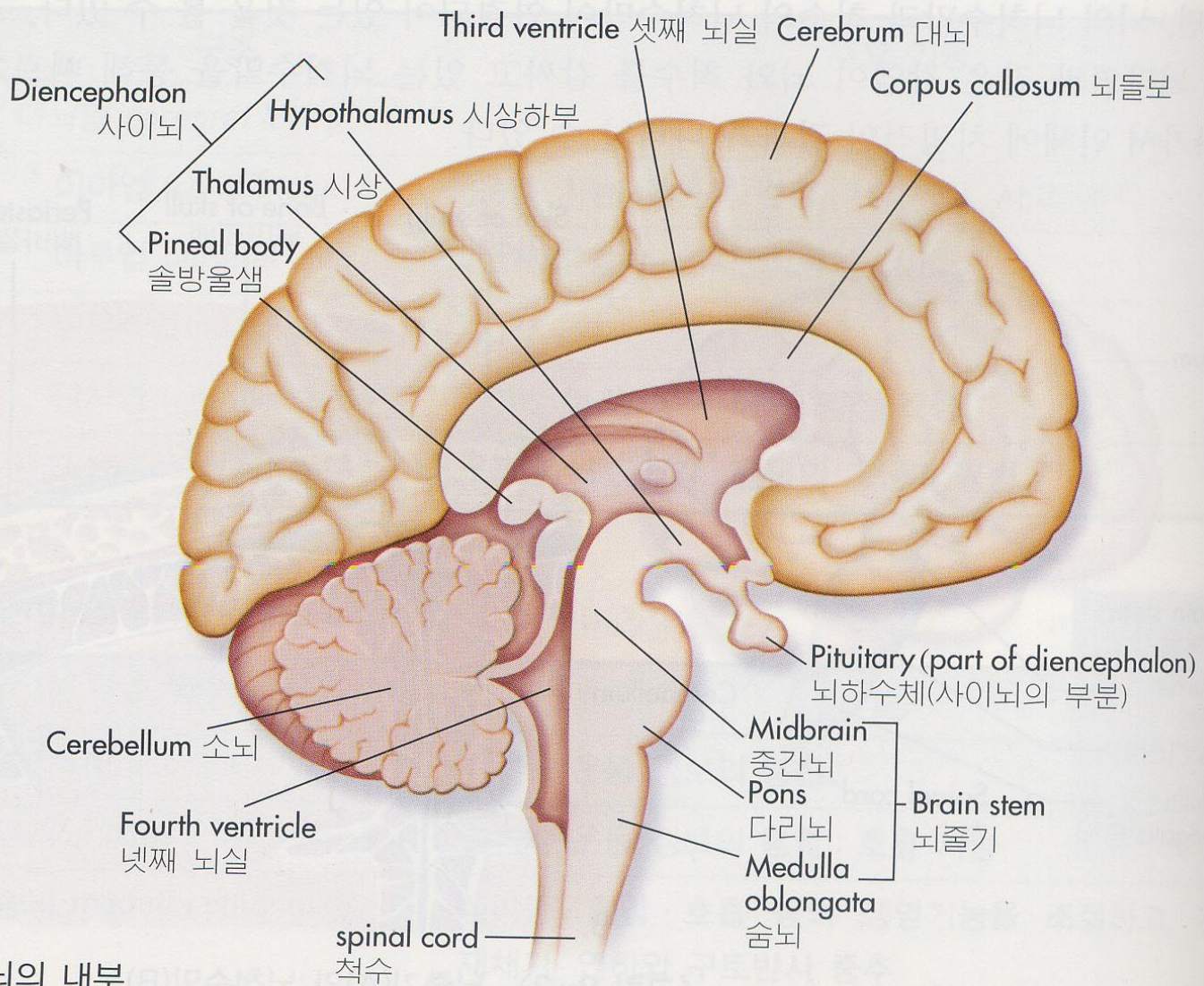
# 간뇌 (사이뇌, Diencephalon)

- 중뇌와 대뇌사이, 3뇌실 양쪽 위치
- 대뇌 반구에 싸여 뇌 중앙에 위치 (하방에서만 관찰)
- 시상 (thalamus) : 감각전도의 중간 중추 (후각 외 감각을 대뇌피질로 전달)
- 시상하부 (hypothalamus) :
  - 자율신경의 통합 중추, **신체 항상성 유지**
  - 체온, 체액, 식욕, 혈당, 배란 조절, 호르몬 생산 (ADH, 옥시토신)

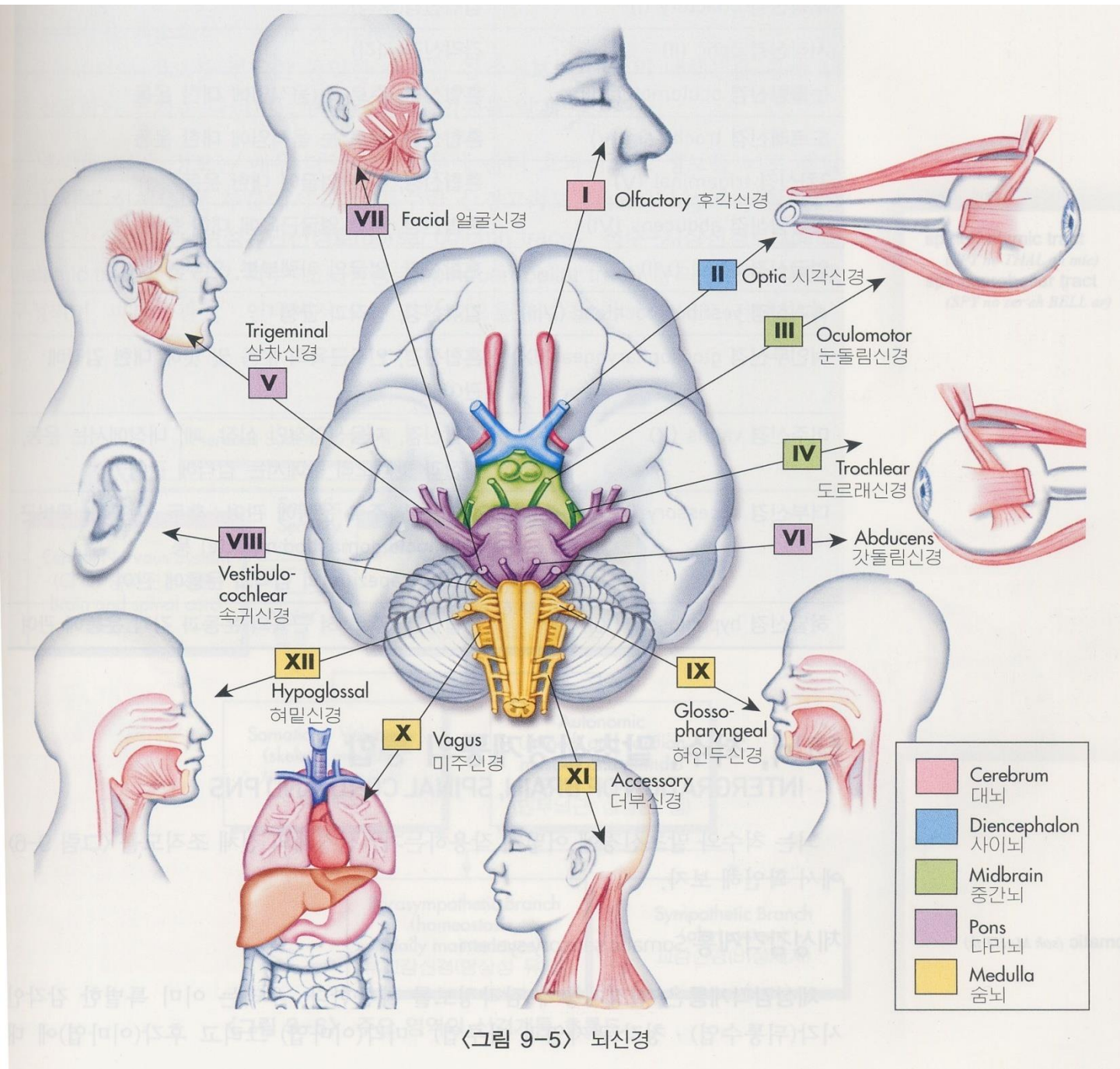
## Diencephalon



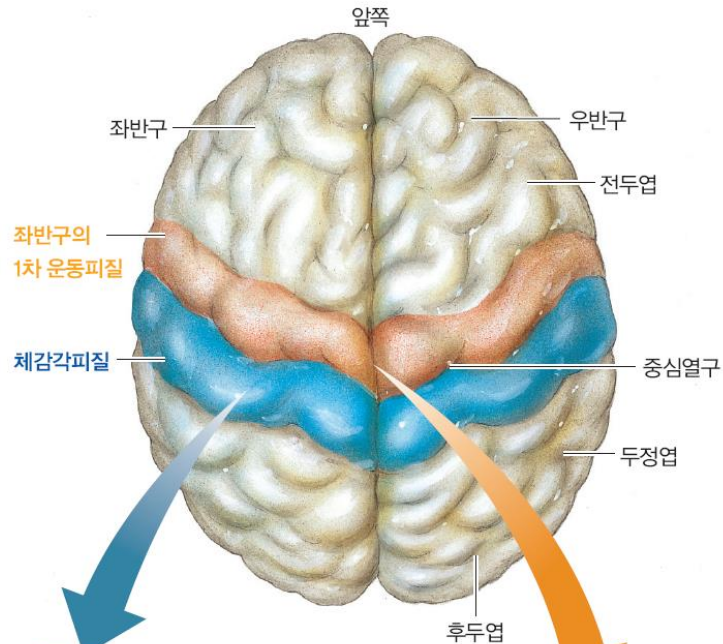




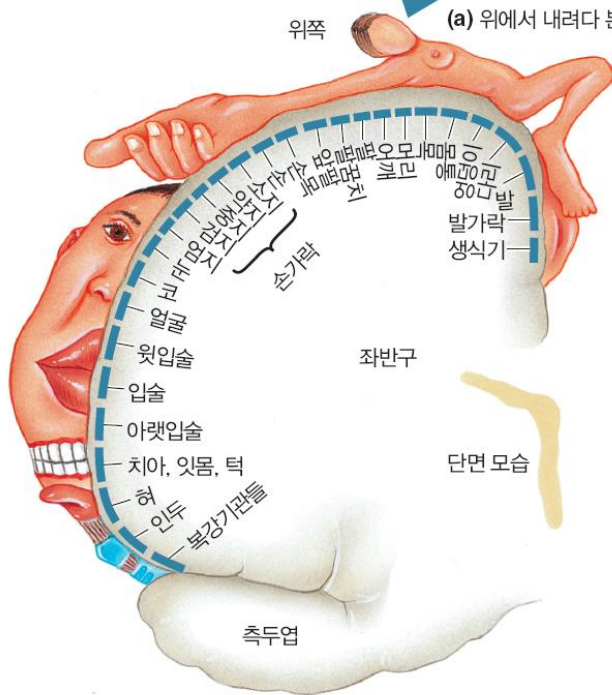
〈그림 9-3〉 뇌의 내부



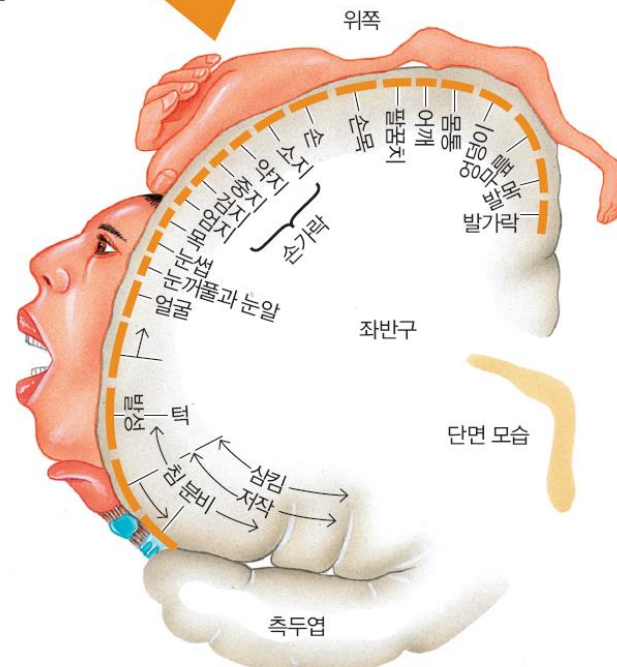
〈그림 9-5〉 뇌신경



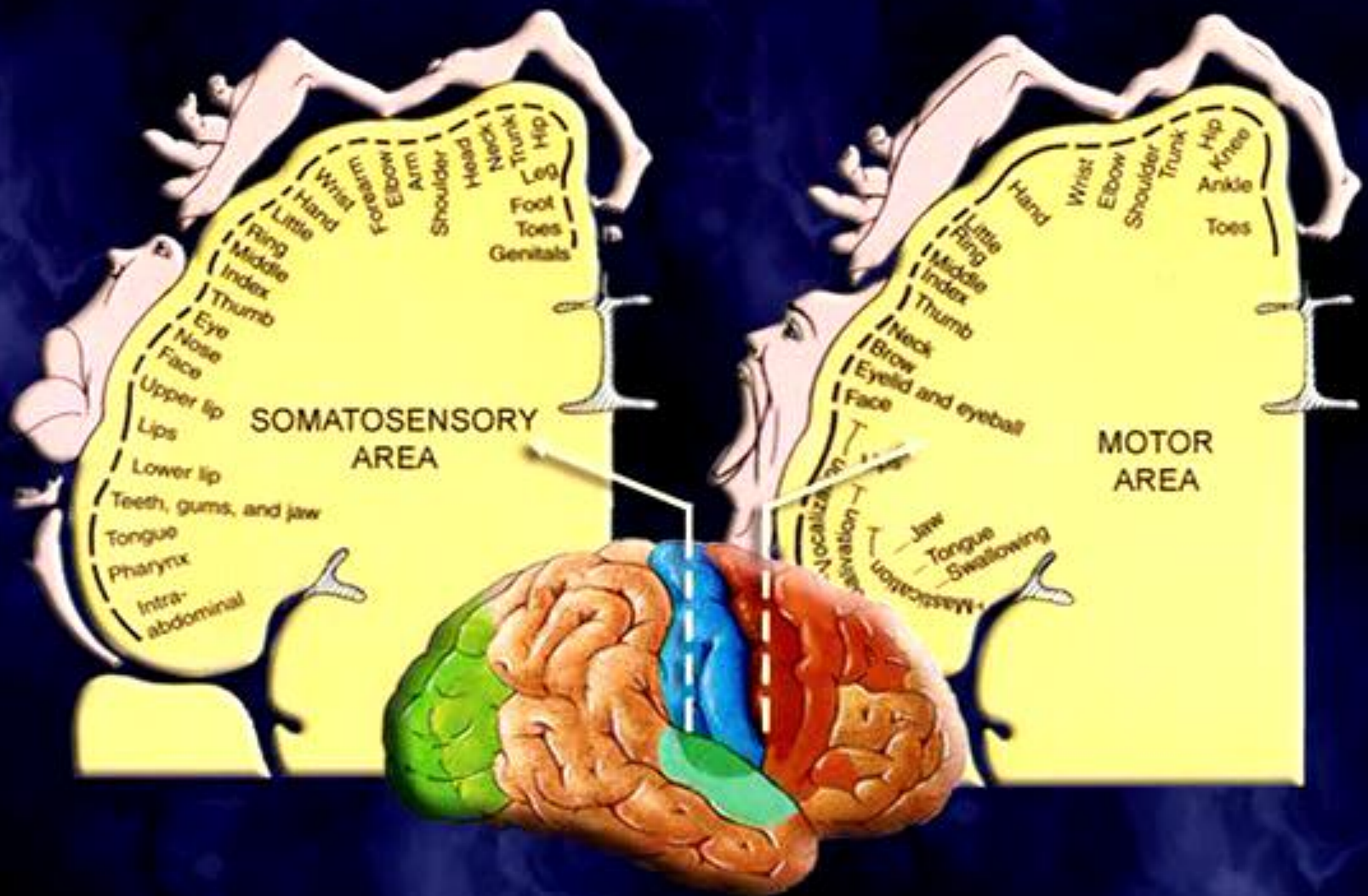
(a) 위에서 내려다 본 뇌의 모습



(b) 감각피질의 인체지도



(c) 운동피질의 인체지도



**homunculus**

